

Society for Vascular Surgery clinical practice guidelines of thoracic endovascular aortic repair for descending thoracic aortic aneurysms

Gilbert R. Upchurch Jr, MD,^a Guillermo A. Escobar, MD,^b Ali Azizzadeh, MD,^c Adam W. Beck, MD,^d Mark F. Conrad, MD,^e Jon S. Matsumura, MD,^f Mohammad H. Murad, MD,^g R. Jason Perry, MD,^h Michael J. Singh, MD,ⁱ Ravi K. Veeraswamy, MD,^j and Grace J. Wang, MD,^k Gainesville, Fla; Atlanta, Ga; Los Angeles, Calif; Birmingham, Ala; Boston, Mass; Madison, Wisc; Rochester, Minn; Seattle, Wash; Pittsburgh and Philadelphia, Pa; and Charleston, SC

ABSTRACT

Thoracic aortic diseases, including disease of the descending thoracic aorta (DTA), are significant causes of death in the United States. Open repair of the DTA is a physiologically impactful operation with relatively high rates of mortality, paraplegia, and renal failure. Thoracic endovascular aortic repair (TEVAR) has revolutionized treatment of the DTA and has largely supplanted open repair because of lower morbidity and mortality. These Society for Vascular Surgery Practice Guidelines are applicable to the use of TEVAR for descending thoracic aortic aneurysm (TAA) as well as for other rarer pathologic processes of the DTA. Management of aortic dissections and traumatic injuries will be discussed in separate Society for Vascular Surgery documents. In general, there is a lack of high-quality evidence across all TAA diseases, highlighting the need for better comparative effectiveness research. Yet, large single-center experiences, administrative databases, and meta-analyses have consistently reported beneficial effects of TEVAR over open repair, especially in the setting of rupture. Many of the strongest recommendations from this guideline focus on imaging before, during, or after TEVAR and include the following:

In patients considered at high risk for symptomatic TAA or acute aortic syndrome, we recommend urgent imaging, usually computed tomography angiography (CTA) because of its speed and ease of use for preoperative planning. Level of recommendation: Grade 1 (Strong), Quality of Evidence: B (Moderate).

If TEVAR is being considered, we recommend fine-cut (≤ 0.25 mm) CTA of the entire aorta as well as of the iliac and femoral arteries. CTA of the head and neck is also needed to determine the anatomy of the vertebral arteries. Level of recommendation: Grade 1 (Strong), Quality of Evidence: A (High).

We recommend routine use of three-dimensional centerline reconstruction software for accurate case planning and execution in TEVAR. Level of recommendation: Grade 1 (Strong), Quality of Evidence: B (Moderate).

We recommend contrast-enhanced computed tomography scanning at 1 month and 12 months after TEVAR and then yearly for life, with consideration of more frequent imaging if an endoleak or other abnormality of concern is detected at 1 month. Level of recommendation: Grade 1 (Strong), Quality of Evidence: B (Moderate).

Finally, based on our review, in patients who could undergo either technique (within the criteria of the device's instructions for use), we recommend TEVAR as the preferred approach to treat elective DTA aneurysms, given its reduced morbidity and length of stay as well as short-term mortality. Level of recommendation: Grade 1 (Strong), Quality of Evidence: A (High).

Given the benefits of TEVAR, treatment using a minimally invasive approach is largely based on anatomic eligibility rather than on patient-specific factors, as is the case in open TAA repair. Thus, for isolated lesions of the DTA, TEVAR should be the primary method of repair in both the elective and emergent setting based on improved short-term and midterm mortality as well as decreased morbidity. (J Vasc Surg 2021;73:55S-83S.)

From the Division of Vascular Surgery, University of Florida, Gainesville^a; the Division of Vascular Surgery, Emory University, Atlanta^b; the Division of Vascular Surgery, Cedars-Sinai, Los Angeles^c; the Division of Vascular Surgery, University of Alabama at Birmingham, Birmingham^d; the Division of Vascular Surgery, Massachusetts General Hospital, Boston^e; the Division of Vascular Surgery, University of Wisconsin, Madison^f; the Knowledge and Evaluation Research Unit, Mayo Clinic, Rochester^g; the Department of Surgery, United States Army, Seattle^h; the Division of Vascular Surgery, University of Pittsburgh Medical Center, Pittsburghⁱ; the Division of Vascular Surgery, Medical University of South Carolina, Charleston^j; and the Division of Vascular Surgery, University of Pennsylvania, Philadelphia.^k

Author conflict of interest: J.S.M. is a consultant and receives research grants through the University of Wisconsin-Madison for Abbott, Cook, Gore, Medtronic, and Endologix. R.K.V. is a proctor and speaker for Cook and Medtronic.

Correspondence: Gilbert R. Upchurch Jr, MD, Department of Surgery, University of Florida, 1600 Archer Rd, Rm 6714, Gainesville, FL 32610 (e-mail: gib.upchurch@surgery.ufl.edu).

Independent peer review and oversight have been provided by members of the SVS Document Oversight Committee (Drs Thomas L. Forbes, Chair, Ruth Bush, Vice-Chair, Neal Barshes, Keith Calligaro, Ronald L. Dalman, Mark Davies, Yazan Duwayri, Alik Farber, Gregory Landry, Mahmoud Malas, Katherine McGinagle, J. Sheppard Mondy, Marc Schermerhorn, and Cynthia Shortell).

0741-5214

Copyright © 2020 by the Society for Vascular Surgery. Published by Elsevier Inc.

<https://doi.org/10.1016/j.jvs.2020.05.076>

TABLE OF CONTENTS

SUMMARY OF RECOMMENDATIONS	56S
DEVELOPMENT OF GUIDELINES	59S
DOCUMENT REVIEW AND APPROVAL	59S
METHODOLOGY AND EVIDENCE REVIEW	59S
EPIDEMIOLOGY AND RISK FACTORS	60S
Population affected	60S
Risk factors for disease and rupture	60S
Natural history and rupture rate of TAA	60S
THE THORACIC AORTA: ANATOMY AND CLASSIFICATIONS	60S
Anatomy of the thoracic aorta	60S
Classifications of the zones and arch	61S
THORACIC AORTIC HISTOPATHOLOGY	61S
Thoracic aneurysm and atherosclerotic disease	61S
Aortic vasculitides and inflammatory diseases	61S
PAU, IMH, and AD	62S
Mycotic aneurysms and aortoesophageal and aortobronchial fistulas	62S
Coarctation	63S
Kommerell diverticulum	63S
Tumors	63S
DIAGNOSTIC EVALUATION OF THORACIC AORTIC DISEASE	63S
Values and preferences	63S
History and physical examination in the evaluation of thoracic aortic disease	63S
History of the patient's illness	63S
Physical examination	64S
Diagnostic studies and imaging in symptomatic patients	64S
Preoperative workup in patients undergoing open surgical and endovascular repair	64S
Emergent or urgent repair	64S
Elective repair	64S
Assessment of left ventricular function	64S
Additional testing	64S
RECOMMENDATIONS FOR IMAGING OF THE DTA BEFORE TEVAR	65S
Chest radiography	65S
CTA	65S
MRA	65S
Intravascular ultrasound (IVUS)	66S
PERIOPERATIVE MANAGEMENT AND OPERATIVE DECISION-MAKING	66S
Perioperative medical management	66S
Open repair vs TEVAR for TAA	66S
Indications for repair	67S
TEVAR for TAA	67S
TEVAR for IMH and PAU	67S
TEVAR for infected TAAs	68S
Choice of anesthetic and monitoring techniques	68S
Anesthesia	68S
Spinal cord protection	68S
Management of the LSA and vertebrobasilar system	69S
Spinal cord ischemia	69S

Stroke	69S
Arm ischemia and vertebrobasilar insufficiency	70S
Additional considerations	70S
Renal protection strategies for TEVAR	71S
Implementation remark	72S
Recommendation for coverage or occlusion of the CA during TEVAR	72S
Recommendation for access during TEVAR ...	73S
Femoral access	73S
Iliac or aortic access	74S
Endoconduit	74S
Carotid-axillary access	75S
Recommendations for treatment of symptomatic and ruptured TAAs	75S
SURVEILLANCE AFTER TEVAR	75S
Implementation remarks about surveillance ..	76S
SPECIAL TAA CONSIDERATIONS	76S
CONCLUSIONS	77S

SUMMARY OF RECOMMENDATIONS

Practice recommendations were made using the Grading of Recommendations Assessment, Development, and Evaluation (GRADE) system.¹

Recommendation 1: In patients considered at low or intermediate risk for a thoracic aortic aneurysm (TAA) based on their history and physical examination findings, we suggest chest X-ray as the first radiographic test as it may identify an alternative diagnosis for symptoms and may obviate the need for additional aortic imaging. **Level of recommendation: Grade 2 (Weak), Quality of Evidence: C (Low)**

Recommendation 2: In patients considered at high risk for symptomatic TAA or acute aortic syndrome, we recommend urgent imaging, usually computed tomography angiography (CTA) because of its speed and ease of use for preoperative planning. Magnetic resonance angiography and transesophageal echocardiography are also adequate for screening to identify thoracic aortic disease but have limited applicability in certain scenarios (discussed further later). **Level of recommendation: Grade 1 (Strong), Quality of Evidence: B (Moderate)**

Recommendation 3: For elective thoracic endovascular aortic repair (TEVAR) cases, we suggest assessment of left ventricular function by transthoracic echocardiography in a patient with dyspnea of unknown origin or in a patient with known congestive heart failure with worsening dyspnea. **Level of recommendation: Grade 2 (Weak), Quality of Evidence: C (Low)**

Recommendation 4: If TEVAR is being considered, we recommend fine-cut (≤ 0.25 mm) CTA of the entire aorta as well as of the iliac and femoral arteries. CTA of the head and neck is also needed to determine the anatomy of the vertebral arteries. **Level of recommendation: Grade 1 (Strong), Quality of Evidence: A (High)**

Recommendation 5: We recommend routine use of three-dimensional centerline reconstruction software

for accurate case planning and execution in TEVAR.
Level of recommendation: Grade 1 (Strong), Quality of Evidence: B (Moderate)

Recommendation 6: We suggest contrast-enhanced magnetic resonance angiography for preoperative planning for patients with severe allergy to iodinated contrast material. **Level of recommendation: Grade 2 (Weak), Quality of Evidence: C (Low)**

Recommendation 7: We recommend intravascular ultrasound use in TEVAR for TAA to assess landing zones when cross-sectional imaging is of poor quality, a more detailed evaluation of landing zones or branch vessel origins is needed, or a decrease in contrast material use is desired. **Level of recommendation: Grade 1 (Strong), Quality of Evidence: B (Moderate)**

Recommendation 8: As hypertension is a modifiable risk factor for the development of aortic aneurysms and is associated with accelerated aortic growth and rupture, we recommend that blood pressure be managed to the adherence of the American College of Cardiology/American Heart Association guidelines.² **Level of recommendation: Grade 1 (Strong), Quality of Evidence: B (Moderate)**

Recommendation 9: We recommend interventions for smoking cessation in patients with thoracic aortic disease as even passive exposure may increase the risk of aortic rupture. **Level of recommendation: Grade 1 (Strong), Quality of Evidence: A (High)**

Recommendation 10: In patients who could undergo either technique (within the criteria of the device's instructions for use), we recommend TEVAR as the preferred approach to treat elective descending thoracic aorta (DTA) aneurysms, given its reduced morbidity and length of stay as well as short-term mortality. **Level of recommendation: Grade 1 (Strong), Quality of Evidence: A (High)**

Recommendation 11: We recommend TEVAR in asymptomatic patients with a descending TAA when the maximum aneurysm diameter exceeds 5.5 cm in "low-risk" patients with favorable aortic anatomy. **Level of recommendation: Grade 1 (Strong), Quality of Evidence: B (Moderate)**

Recommendation 12: We suggest using higher aortic diameter thresholds for TEVAR in patients deemed to have a particularly high risk of death, renal failure, or paraplegia from the procedure, where the benefit of treatment is lower than the risk posed by the natural history of the TAA. **Level of recommendation: Grade 2 (Weak), Quality of Evidence: C (Low)**

Recommendation 13: Because of the dynamic nature of isolated intramural hematoma (IMH) and its known association with aortic dissection, we recommend close observation and hypertension control with follow-up imaging as the initial management of patients with asymptomatic IMH. **Level of recommendation: Grade 1 (Strong), Quality of Evidence: B (Moderate)**

Recommendation 14: We recommend TEVAR in patients with IMH or penetrating aortic ulcer who have persistent symptoms or complications or show evidence of disease progression on follow-up imaging after a period of hypertension control. **Level of recommendation: Grade 1 (Strong), Quality of Evidence: B (Moderate)**

Recommendation 15: We suggest TEVAR in selected cases of asymptomatic penetrating aortic ulcer in patients who have at-risk characteristics for growth or rupture. **Level of recommendation: Grade 2 (Weak), Quality of Evidence: B (Moderate)**

Recommendation 16: We suggest TEVAR for symptomatic mycotic/infected TAA as a temporizing measure, but data demonstrating long-term benefit are lacking. **Level of recommendation: Grade 2 (Weak), Quality of Evidence: C (Low)**

Recommendation 17: We recommend increasing perfusion pressure through controlled hypertension (mean arterial pressure >90 mm Hg) as a component of a spinal cord protection protocol in patients at high risk of spinal cord injury because of extensive coverage length (>15 cm), poor hypogastric perfusion (occluded or significantly stenosed hypogastric arteries), or coverage of important collaterals (subclavian/hypogastric arteries). **Level of recommendation: Grade 1 (Strong), Quality of Evidence: B (Moderate)**

Recommendation 18: We recommend prophylactic cerebrospinal fluid drainage for spinal cord injury protection in TEVAR cases that are deemed high risk (covering extensive length of descending aorta; previous aortic coverage, including endovascular aneurysm repair and open abdominal aortic aneurysm repair; compromised pelvic perfusion with diseased or occluded common or internal iliac arteries; diseased or occluded vertebral arteries; planned left subclavian artery [LSA] coverage; or deemed high risk by the operating surgeon). **Level of recommendation: Grade 1 (Strong), Quality of Evidence: B (Moderate)**

Recommendation 19: For elective TEVAR of a TAA where coverage of the LSA is necessary for adequate stent graft seal, we suggest preoperative or concomitant LSA revascularization. **Level of recommendation: Grade 1 (Strong), Quality of Evidence: B (Moderate)**

Recommendation 20: For patients in whom the anatomy to be treated compromises perfusion to vital structures, we recommend LSA revascularization. **Level of recommendation: Grade 1 (Strong), Quality of Evidence: B (Moderate)**

Examples of these circumstances include the following:

Presence of a patent left internal mammary artery to coronary artery bypass graft
Termination of the left vertebral artery into the posterior inferior cerebellar artery
Absent, atretic, or occluded right vertebral artery
Patent left arm arteriovenous shunt for dialysis

Prior infrarenal aortic operation or endovascular aneurysm repair with previously ligated or covered lumbar and middle sacral arteries

Planned extensive coverage (≥ 15 cm) of the DTA

Hypogastric artery occlusion or significant occlusive disease

Presence of aneurysm disease in the young patient, for whom future therapy involving the distal thoracic aorta may be necessary

Recommendation 21: For patients with acute thoracic emergencies, where TEVAR is required urgently and coverage of the LSA is necessary, it is suggested that revascularization should be individualized and addressed on the basis of the patient's anatomy and urgency of the procedure. **Level of recommendation: Grade 2 (Weak), Quality of Evidence: B (Moderate)**

Recommendation 22: We recommend preprocedural TEVAR planning to include sizing and landing sites before the case to minimize procedural contrast material use. If available, intraoperative CTA overlay technology and intravascular ultrasound should be used to minimize use of contrast material. **Level of recommendation: Grade 1 (Strong), Quality of Evidence: B (Moderate)**

Recommendation 23: We recommend nonionic, hypo-osmolar contrast material with attempts at minimizing intra-arterial contrast agent use, especially in patients at high risk for contrast-induced nephropathy. **Level of recommendation: Grade 1 (Strong), Quality of Evidence: B (Moderate)**

Recommendation 24: Depending on the patient's corporal density and the capacity of the X-ray equipment available, we suggest diluting contrast material in the power injector when possible (typically to 50% or 70%). Adjustments in injection volume and time (faster injection of smaller doses) can usually compensate when additional visibility is required. **Level of recommendation: Grade 2 (Weak), Quality of Evidence: C (Low)**

Recommendation 25: We suggest the use of on-table mapping software options on fixed-imaging X-ray systems, such as roadmapping and computed tomography (CT) fusion or overlay reference, to aid in locating target landing sites and to minimize need for repeated injections. If available, CT overlay capability is extremely useful, especially in cases in which location and cannulation of branches will be needed. **Level of recommendation: Grade 2 (Weak), Quality of Evidence: B (Moderate)**

Recommendation 26: To decrease the risk of atheroembolization, we recommend minimizing intra-aortic wire, catheter, and endograft manipulation in the aortic arch and at or above the visceral/renal arteries, especially in patients with significant aortic atheromatous disease or thrombus. **Level of recommendation: Grade 1 (Strong), Quality of Evidence: B (Moderate)**

Recommendation 27: We recommend minimizing the dwelling time of large or occlusive iliofemoral artery sheaths to decrease the risk of spinal cord ischemia and lower extremity ischemia that can lead to postoperative compartment syndrome or rhabdomyolysis. In cases in which a large sheath must be left in place for a prolonged time, it can be withdrawn into the external iliac artery to allow antegrade flow into the ipsilateral internal iliac artery. Meticulous postoperative vigilance to detect inadequate lower extremity perfusion or compartment syndrome should be routine. **Level of recommendation: Grade 1 (Strong), Quality of Evidence: B (Moderate)**

Recommendation 28: We recommend pre-emptive superior mesenteric artery (SMA) stenting with a balloon-expandable stent in cases of $>50\%$ stenosis of the SMA in the following conditions: before or after celiac artery (CA) coverage or encroachment, with TEVAR that is encroaching on the SMA origin, or in any patient otherwise considered at high risk for post-TEVAR mesenteric ischemia. **Level of recommendation: Grade 1 (Strong), Quality of Evidence: B (Moderate)**

Recommendation 29: In anticipation of high risk for CA territory ischemia (nonvisualization of CA collateral branches by CTA or dedicated SMA angiography), we recommend open or endovascular revascularization of the CA before TEVAR. **Level of recommendation: Grade 1 (Strong), Quality of Evidence: B (Moderate)**

Recommendation 30: If an open approach for access is used, we recommend transverse or oblique incisions in performing open femoral access for TEVAR. **Level of recommendation: Grade 1 (Strong), Quality of Evidence: B (Moderate)**

Recommendation 31: We recommend using ultrasound guidance for percutaneous access to improve procedural success and to decrease the rate of major complications. **Level of recommendation: Grade 1 (Strong), Quality of Evidence: B (Moderate)**

Recommendation 32: We recommend that percutaneous access for TEVAR is safe and an acceptable alternative to open common femoral artery exposure if certain anatomic criteria are met (eg, diameter of common femoral artery, lack of front wall calcium). **Level of recommendation: Grade 1 (Strong), Quality of Evidence: B (Moderate)**

Recommendation 33: We recommend the use of iliac conduits or direct iliac/aortic punctures for TEVAR delivery to facilitate access in patients with small (relative to the chosen device), tortuous, or calcified iliac vessels. The decision to perform a conduit should be made in the preoperative setting, when possible. **Level of recommendation: Grade 1 (Strong), Quality of Evidence: B (Moderate)**

Recommendation 34: We suggest that endoconduits to facilitate access for TEVAR are an acceptable alternative to an open iliac conduit in some cases, but few

data comparing them with an iliac conduit or long-term data describing their outcomes over time are available.

Level of recommendation: Grade 2 (Weak), Quality of Evidence: C (Low)

Recommendation 35: We recommend TEVAR over open repair for the treatment of ruptured DTA when anatomically feasible. **Level of recommendation: Grade 1 (Strong), Quality of Evidence: B (Moderate)**

Recommendation 36: We recommend contrast-enhanced CT scanning at 1 month and 12 months after TEVAR and then yearly for life, with consideration of more frequent imaging if an endoleak or other abnormality of concern is detected at 1 month. **Level of recommendation: Grade 1 (Strong), Quality of Evidence: B (Moderate)**

DEVELOPMENT OF GUIDELINES

The Society for Vascular Surgery (SVS) thoracic endovascular aortic repair (TEVAR) guidelines committee was created by first soliciting interest among members of the SVS. The committee and Chair were then chosen by the SVS to ensure that the number of authors without documented conflicts of interest was greater than or equal to the number with reported conflicts of interest. Importantly, these guidelines are specific for lesions isolated to the descending thoracic aorta (DTA) that require coverage of zones 2 to 6.³ Those patients with aortic disease within the aortic arch requiring coverage at or proximal to the left carotid artery (zone 0 or zone 1) are excluded from these guidelines. Furthermore, whereas we included management of the celiac artery (CA) when coverage is required for distal seal and fixation, the subject of management of any other visceral arteries was excluded from these guidelines.

An outline developed by the writing group included the following: anatomy of the thoracic aorta; aortic pathologic processes to be covered, that is, thoracic aortic aneurysms (TAAs) and acute aortic syndromes limited to penetrating aortic ulcer (PAU) and intramural hematoma (IMH), exclusive of traumatic injuries and dissection; diagnostic findings; and comparison of the advantages and disadvantages of available imaging modalities in various settings. Further topics included the perioperative management of patients with thoracic aortic disease, specifically mitigation of the perioperative risk of spinal cord ischemia, stroke, and renal failure, and evidence-based recommendations regarding the management of the left subclavian artery (LSA) and CA when coverage of those vessels is deemed necessary for "successful" repair. Additional recommendations focused on arterial access, differential management of elective and urgent/emergent TAA, and optimal surveillance intervals after TEVAR. Finally, we considered special problems, including

possible volume-outcome relationship, related to repair of TAA.

DOCUMENT REVIEW AND APPROVAL

The committee developed the practice guideline by assigning members to create primary drafts of each section of the document based on the aforementioned outline, highlighting specific areas where recommendations were needed and appropriate. Each section was then placed into a single document, compiled, reviewed, and revised by the writing group, led by the Chair. All guideline recommendations were reviewed by the full committee and finalized through an iterative, consensus process. In considering available treatment modalities to be included in the final draft, we evaluated only options currently available to patients and physicians in the United States.

The Grading of Recommendations Assessment, Development, and Evaluation (GRADE) framework was used for determining the quality of evidence and the strength of recommendation, as previously reported.¹ The quality of evidence is rated high (A), moderate (B), or low (C). This rating is based on the risk of bias, precision, directness, and consistency. The strength of recommendation is graded on the basis of the quality of evidence, balance between benefits and harms, patients' values, preferences, and clinical context. Recommendations are graded strong (1) or weak (2). The term *we recommend* is used with strong recommendations, and the term *we suggest* is used for weak recommendations. Some statements are labeled good practice statements.⁴ These are statements that did not have direct supporting evidence but had ample indirect evidence and would be considered by many surgeons as surgical principles. Some statements are labeled implementation remarks. These are technical suggestions that aim to explain and to implement the preceding recommendation.

Finally, the SVS Document Oversight Committee peer reviewed the document twice and provided content and methodology expertise. The document was then revised and sent to the Executive Committee and received final endorsement.

METHODOLOGY AND EVIDENCE REVIEW

In association with the TEVAR for TAA guideline group document and recommendations, a systematic review and meta-analysis were conducted to evaluate the effectiveness of TEVAR and open repair in patients with isolated TAA.⁵ The data sources for this evidence review included PubMed, Ovid MEDLINE, Ovid Embase, EBSCO CINAHL, and Scopus, which were searched from each database's inception to January 29, 2016. Observational studies that compared the two approaches in adults with TAA and reported 30-day mortality or procedure complications were selected. Data were extracted and appraised by two reviewers independently. Random

effects meta-analysis was used to estimate odds ratio (OR) and 95% confidence intervals (CIs). This document provided evidence that TEVAR reduced the risk of mortality in both intact (OR, 0.6; 95% CI, 0.36-0.99) and ruptured (OR, 0.58; 95% CI, 0.38-0.88) settings. In addition, paraplegia risks and pulmonary complication rates were lower with TEVAR compared with open repair for isolated TAA.

EPIDEMIOLOGY AND RISK FACTORS

Thoracic aortic disease is an important public health issue.⁶⁻¹⁰ Although abdominal aortic aneurysms (AAAs) and ascending aortic aneurysms are more common, descending TAAs and thoracoabdominal aortic aneurysms (TAAAs) are not rare, with an estimated incidence of 6 to 10 cases per 100,000 person-years.^{5,10} Olsson et al¹¹ examined the prevalence of TAA from 1987 to 2002 in patients with thoracic aortic dissections (ADs) or aneurysms in Sweden. Of 14,229 individuals with thoracic aortic disease, the diagnosis was made in 11,039 (78%) before death. The incidence of thoracic aortic disease rose by 52% in men and 28% in women to reach 16.3 and 9.1 per 100,000 per year, respectively. The authors concluded that the prevalence and incidence of thoracic aortic disease were higher than previously reported and have been steadily increasing. The rising prevalence of TAA has been attributed to a number of factors, including improved imaging techniques, an aging population, and increased patient and physician awareness.¹²

Population affected. TAA is primarily a disease of the elderly. The average age of patients with TAA is 65 years at diagnosis, with a male to female ratio of 1.7:1.¹⁰ In contrast, in patients with AAA, the mean age is 75 years, with a male to female ratio of 6:1.¹³ TAAs clearly have a genetic component, with >20% of patients having a first-degree relative affected by aneurysm disease.¹⁴⁻¹⁶

Risk factors for disease and rupture. Many risk factors are common to both AAA and TAA patients, including hypertension, smoking, and atherosclerosis in other arterial beds.^{10,17-19} Systemic hypertension, especially elevated diastolic blood pressure >100 mm Hg, has been associated with aortic growth and rupture.^{20,21} Although most often described as degenerative in etiology, up to 20% of patients have TAAs that are the sequelae of chronic AD. Importantly, for this document, TAA related to chronic type B ADs and those associated with inherited connective tissue disorders are intentionally excluded and are the subject of future SVS documents.

Natural history and rupture rate of TAA. Published data on the natural history of *isolated* TAAs is not as readily available as it is for infrarenal AAA, partially related to their much less frequent occurrence. Also, data regarding isolated TAA have historically been combined with TAAA and with aneurysm associated with dissection, each of which is likely to have its own unique

natural history, further clouding our knowledge.²² Importantly, TAAs often occur in patients with multiple comorbidities, such as hypertension and atherosclerosis, over a wide range of ages. Therefore, patients often succumb to other disease processes, such as cancer or coronary artery disease, highlighting the importance of preoperative surgical decision-making in the setting of the largely unknown natural history of TAA.

Regardless, initial studies from the 1970s by McNamara and Pressler²³ documented that approximately 40% of TAA patients who did not undergo surgical repair died of rupture, whereas 32% died of other cardiovascular diseases, with a mean survival of <3 years after TAA diagnosis. During an extended period of observation, >90% of patients with unrepaired aneurysms suffered aortic rupture, with 68% of ruptures occurring >1 month after the diagnosis.^{23,24} A more recent (2002) review²⁵ found the 5-year survival rate for patients with a 6.0-cm TAA to be 54%, with a risk for rupture of 3.7%/y and a risk for death of 12%/y. The investigators found a similar median survival in patients with untreated TAA of only 3.3 years. In a natural history study by Crawford and DeNatale²⁶ of TAA patients who were not candidates for open surgery, the survival rate was just 24% at 2 years, with more than half the deaths related to aneurysm rupture. Chronic obstructive pulmonary disease (COPD) was noted in 80% of the subgroup with rupture. Similar studies in patients with small infrarenal AAAs have confirmed COPD as a significant risk factor for rupture.²⁷ Cambria et al²⁸ followed up a series of 57 patients with TAA, including those who were not considered operative candidates. The authors found that an aneurysm >5 cm ($P = .05$) and both COPD and chronic renal failure were associated with rupture ($P = .06$). Griep et al²⁹ studied 165 patients with TAAA who did not undergo surgery, finding that about 20% experienced aneurysm rupture. Significant risk factors included older age, COPD, continued pain, and aortic diameter. Patients with AD ruptured at smaller aortic diameters than did those with degenerative aneurysms.

Practice Statement: More research focused on the pathogenesis and clinical care of patients with isolated TAA is required.²²⁻²⁹ **(Ungraded good practice statement)**

THE THORACIC AORTA: ANATOMY AND CLASSIFICATIONS

Anatomy of the thoracic aorta. The thoracic aorta is divided into the aortic root, ascending aorta, aortic arch, and descending aorta. The size of the thoracic aorta increases from the root to the diaphragm, with an average size between 2 and 3 cm; it is approximately 10% smaller in women.^{6,30} Critically at risk during TEVAR are the multiple spinal cord branches that may be covered by the endograft after emerging as dorsal branches from the intercostal arteries. These critical

branches collateralize as the anterior spinal artery, which then travels along the axis of the cord. Multiple vessels supply blood flow to the spinal cord, including the subclavian and vertebral arteries, intercostal arteries, supreme intercostal artery of Adamkiewicz, lumbar arteries, and iliolumbar branches of the internal iliac (hypogastric) arteries.^{31,32}

There are anatomic aortic arch variations. These variations often are not manifested during childhood but are recognized later in life. Many of these variations are often corrected in childhood if they are incompatible with a normal life span. The most common anatomic variation is a “bovine” arch, in which one or more of the great vessels arise from a common trunk. A second common variable, the aberrant right subclavian artery (*arteria lusoria*), arises distal to the LSA and travels posterior to the esophagus to the right arm. The path of these aberrant arteries can vary in their relation to the trachea and esophagus. Other common variants include an aberrant LSA, which often is seen in the setting of a right-sided arch, and a thyroid ima branch, which arises directly from the aortic arch and travels to the thyroid gland. Variations in the origin of the vertebral arteries are also common, with the most common variation involving a vertebral artery arising directly from the aortic arch.

Classifications of the zones and arch. The aorta can be divided into 11 zones, 6 of which are in the thoracic aorta, which are useful for describing the segment of the vessel and the potential branches that may be covered or replaced during repair (Fig 1).³ The utility of these zones in comparative research is well described in the SVS Ad Hoc Committee on TEVAR Reporting Guidelines.³ Zone 2 is the segment that includes the LSA, whereas zone 3 is the considered the proximal DTA. Zone 4 is the straight portion of descending aorta. Zone 5 is the segment of the DTA that terminates above the CA. The remainder of the aorta lies within the abdomen, with zone 6 involving the celiac aorta (Fig 1). Aortic arch anatomy also can be critical, especially in the setting of a type III arch (Fig 2).³³

Practice Statement: Future publications and reporting of TEVAR management should include classifications identifying the location of aneurysms and presence or absence of PAUs with or without IMH as well as the zones and arch type to aid in comparative studies for the prediction of patient outcomes after interventions. (Ungraded good practice statement)

THORACIC AORTIC HISTOPATHOLOGY

Thoracic aneurysm and atherosclerotic disease. The most common histopathologic feature of TAA is elastic tissue fragmentation and loss of smooth muscle cells, resulting in the collection of matrix material in the area of disintegration. These medial degenerative changes

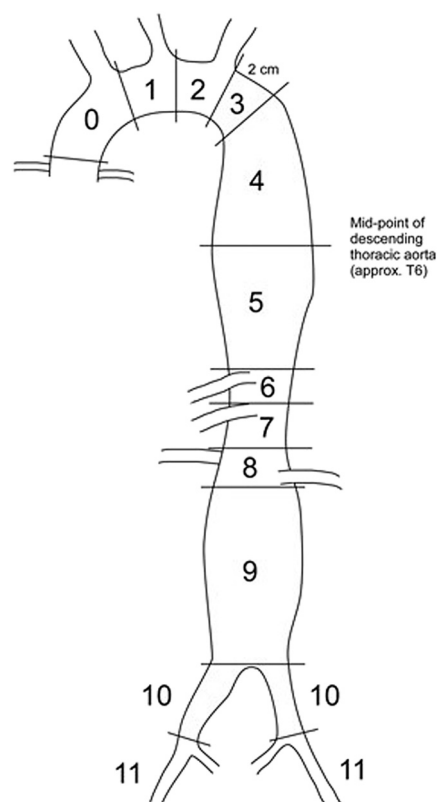


Fig 1. Zones of the thoracic aorta.³

are variably associated with wall thinning, loss of elastic and muscle fibers in the aortic media, accumulation of mucopolysaccharide cysts between the fibers, and subsequent wall expansion. Common risk factors include hypertension and connective tissue disease. Atherosclerosis, on the other hand, is typically characterized by intimal plaques composed of variable combinations of fibrous tissue and lipid with calcification. Inflammation manifested by the accumulation of macrophages and lymphocytes and their secretory products contributes to the progression of disease.

Aortic vasculitides and inflammatory diseases. Inflammatory aortitis is characterized by the presence of inflammation of the adventitia and media.³⁴ Histologic findings may show thickened adventitia with infiltration of adventitia and media with clusters of plasma cells and lymphocytes.

Takayasu (necrotizing) aortitis usually is manifested as pan-aortitis with granulomatous inflammation and stenosis of the aortic arch and its major branches.³⁴ Initially, the inflammation is around the vasa vasorum and at the medial-adventitial site and advances into the intima. Rapid and severe inflammation can lead to the loss of smooth muscle cells and may advance to produce aortic arch syndrome, segmental stenosis, occlusion, and aneurysm. Disintegration of elastic fibers is prominent, as are reactive fibrosis and increased ground substance within

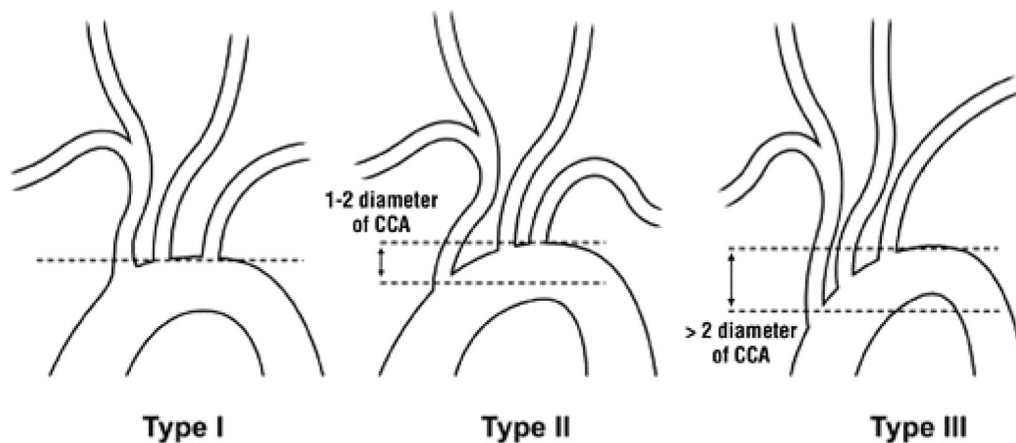


Fig 2. Classification of the aortic arch. CCA, Common carotid artery. (Reproduced from Madhwal S, Rajagopal V, Bhatt DL, Bajzer CT, Whitlow P, Kapadia SR. Predictors of difficult carotid stenting as determined by aortic arch angiography. *J Invasive Cardiol* 2008;20:200-4. Permission from HMP Global.)

the intima. The histologic hallmark of Takayasu aortitis is multifocal medial laminar necrosis rimmed by macrophages and occasional giant cells. Quiescent or “burnt out” Takayasu disease is characterized by dense adventitial fibrous thickening and marked medial fibrosis with loss of the normal lamellar structure.

Giant cell arteritis is a systemic vasculitis characterized by focal, transmural granulomatous inflammation with giant cells, intimal thickening, and infiltrates of mononuclear cells, neutrophils, and eosinophils.³⁴ This manifestation is called granulomatous arteritis. The key characteristic of granulomatous arteritis is the segmental spread of inflammatory infiltrates, made up of T cells and histiocytes, that results in “skip lesions.” Both Takayasu aortitis and giant cell arteritis are large-cell vasculitides that appear to be the target of new medical management that include the use of targeted biologics.³⁵

PAU, IMH, and AD. PAU and IMH, a complex spectrum of aortic disease, are unique but often intertwined pathologic processes. This document is not intended to provide a review of AD as it will be reviewed in separate SVS guidelines.

Briefly, an atherosclerotic plaque can ulcerate and result in a limited dissection or PAU.³⁶ The ulceration penetrates the internal elastic lamina, resulting in hematoma formation within the media. The plaque may precipitate a localized intramedial dissection associated with a variable amount of IMH within the aortic wall, which can spread into the adventitia, forming a pseudoaneurysm or causing rupture. PAUs are typically not aneurysmal but can occur concurrently with or in the absence of an aortic aneurysm, dissection, or IMH.

IMH can also develop in apparent isolation in patients with mild or no atherosclerosis. Aortic IMH may represent a variant of dissection, the so-called dissection in evolution, and is characterized by the absence of an intimal flap, re-entrant tear, or double channel with false lumen.

It is speculated that the vasa vasorum is responsible for IMH, with elevated pressures in the vasa vasorum leading to rupture within the aortic wall. Subsequently, progression and eventual rupture into the intima might occur, leading to typical AD. Studies examining the vasa vasorum have also suggested that hyperplasia leading to chronic, occlusive disease within the aortic wall can lead to chronic medial ischemia and degeneration. The complex pathologic processes of PAUs and IMH have been well described,³⁷⁻³⁹ and management decisions can often be complex, depending on the clinical presentation and anatomic location, among other important factors.

Mycotic aneurysms and aorto-esophageal and aorto-bronchial fistulas. A mycotic (or infected) aneurysm is defined as an infectious break in the wall of an artery with formation of a blind, often saccular outpouching that is contiguous with the arterial lumen. Controversy has existed as to the exact mechanisms by which primary mycotic TAAs occur; they may be due to hematogenous dissemination of microorganisms, direct involvement of the intima, or extension from a nearby septic focus. An intimal disruption, such as in atherosclerotic plaque, may be a site of bacterial lodgment, and histologic specimens have often demonstrated neutrophilic infiltration and atherosclerotic change in the same aortic wall. Pre-existing trauma or aneurysm may also facilitate the onset of the infectious process. Histopathologic findings consist of variable elastic fiber degeneration, partial or complete lumen obliteration, compensatory fibrosis with increased thickness of the aortic wall, and perivascular chronic infiltrate. It is important to exclude infection in all saccular TAAs as ~93% of mycotic aneurysms have this appearance on computed tomography angiography (CTA).⁴⁰

Aorto-esophageal fistula is a rare and potentially fatal disorder that often is manifested after rupture of an

aneurysm into the esophagus. The main etiologic factor contributing to aortoesophageal fistula is aortic disease, with more than half of cases being secondary to rupture of an aneurysm of the DTA into the esophagus. Aortobronchial fistula⁴¹ is also a rare but potentially life-threatening cause of hemoptysis if it is not adequately treated. In younger patients, aortobronchial fistula is more frequently seen secondary to surgical repair of congenital heart defects and aortic coarctation repair. However, most aortobronchial fistulas originate from a descending atherosclerotic aneurysm or pseudoaneurysm, which causes an erosion of the lung parenchyma or tracheobronchial tree.

Coarctation. Aneurysm formation can also develop in patients late after surgical repair of aortic coarctation in infancy and has been reported in numerous patients, with as many as 7% of patients developing “local” aneurysms.⁴² These aneurysms may be manifested as false, true, or dissecting.⁴³ Cystic medial necrosis is a common histopathologic feature observed in coarctation specimens from surgery or autopsy. This provides a pathologic basis for the formation of aneurysms observed in these patients after balloon angioplasty or repair.

Kommerell diverticulum. Kommerell diverticulum is a bulbous aortic dilation that is a remnant of incomplete regression of an embryologic aortic arch; it is usually located at or near the origin of an aberrant subclavian artery (ASA).⁴⁴ Aberrant right and left subclavian arteries (in a right-sided aortic arch) are typically associated with a Kommerell diverticulum. The right ASA can arise distal to the LSA and crosses through the posterior mediastinum behind the esophagus on its way to the right upper extremity. The aberrant vessel has the potential to cause a vascular ring around the trachea and esophagus, causing dysphagia and palsy of the recurrent laryngeal nerve due to anatomic position. Aneurysms rarely involve the ASA, but they are associated with a high mortality rate if they rupture. The risk for rupture or dissection is variable and ranges from 19% to 53% in some of the case report series.⁴⁵ Surgical intervention should be considered when the diameter of the diverticulum exceeds 30 mm or the diameter of the descending aorta adjacent to the diverticulum exceeds 50 mm.⁴⁶⁻⁴⁸ Histologic studies demonstrated the presence of cystic medial necrosis in the diverticulum wall, which would explain the reported high rates of AD and rupture associated with these diverticula.

Tumors. Primary malignant tumors of the aorta are extremely rare and exhibit enormous histologic heterogeneity.⁴⁹ They have been described as three distinct morphologic types: intraluminal, intimal, and adventitial. Most of the cases are sarcomas, followed by malignant fibrous histiocytomas. Although intra-aortic biopsy is possible, these tumors are rarely expected or diagnosed before surgical exploration.

Practice Statement: There is a relative lack of high-quality, long-term evidence on the use of TEVAR in the setting of arteritis,⁵⁰ aortoesophageal⁵¹ and aortobronchial⁴¹ fistulas, coarctation,⁴³ Kommerell diverticulum,⁵² and tumors.⁵³ Therefore, no strong recommendations can be made. However, it is recognized that there are numerous institutional and database reports documenting the use of TEVAR in these settings. It is likely, especially in the setting of a ruptured thoracic aorta in association with these various pathologic processes, that TEVAR can play a lifesaving role. Finally, there is also likely to be an advantage to TEVAR in these pathologic processes in the noninfectious setting over the infectious ones. **(Ungraded good practice statement)**

DIAGNOSTIC EVALUATION OF THORACIC AORTIC DISEASE

Thoracic aortic disease is increasingly an incidental finding on studies performed for other indications because of the increasing use of cross-sectional imaging. Unlike abdominal ultrasound for screening for AAAs, there is no low-cost modality that can be used to image DTA disease. Thus, there is more reliance on the patient's history, including familial history, as well as on physical examination findings to guide the ordering of radiographic tests to screen for thoracic aortic disease. Genetic testing lends further support for diagnostic imaging. This section is dedicated to the diagnostic evaluation of a patient with DTA disease and also discusses specifics of the history and physical examination as well as the preoperative workup for patients before they undergo TEVAR.

Values and preferences

The committee acknowledges the lack of high-quality evidence supporting specific screening strategies, particularly as it pertains to screening intervals. The committee placed high value on preventing catastrophic vascular events and lower value on screening burdens (including psychological burdens) and costs.

History and physical examination in the evaluation of thoracic aortic disease

History of the patient's illness. The clinical history should be directed toward determining whether the patient is at elevated risk for TAA and should receive further diagnostic evaluation. Most patients are older, with uncontrolled hypertension as a primary risk factor. In younger patients, the clinical history should lead to an evaluation for secondary causes of severe hypertension, including the use of legal and illicit sympathomimetic drugs, especially in patients with syndromic and nonsyndromic genetic defects predisposing to aortic disease. Patients with an inflammatory vasculitis, such as Takayasu disease, giant cell arteritis, and Behçet arteritis, should also be considered at high risk for development of TAA. The history should also focus on history of previous aortic coarctation repair or a history of significant

blunt trauma to the chest (especially those with a rapid deceleration injury). A detailed family history should be taken to elicit a history of familial TAA and dissection. The past surgical history is carefully reviewed with specific attention to prior procedures, including internal mammary artery to coronary artery transposition, upper extremity arterial procedures, and hemodialysis access procedures. The history should also focus on history of aortic valve disease, recent catheterization of the aorta, and known TAA, especially in the ascending aorta and aortic arch. Patients may also have symptoms attributable to compression of adjacent structures in the thorax, such as dysphagia, shortness of breath, or hoarseness related to stretching of the recurrent laryngeal nerves, especially in the setting of a large or saccular proximal DTA aneurysm.

Physical examination. All patients should undergo a detailed physical examination designed to first detect the presence of a genetic syndrome associated with AD or TAA (eg, Marfan, Loeys-Dietz, Ehlers-Danlos, or Turner syndrome). It is well known that these patients with genetic syndromes have aneurysms in other anatomic locations, and thus palpation of the abdomen and popliteal fossa for aneurysms should be a routine part of the physical examination.

The history and physical examination should also be focused on identifying other factors, such as angina or COPD, that might preclude the patient from undergoing TEVAR, especially in the setting of general anesthesia. Physical examination should also include a pulse evaluation, with special attention paid to the presence of palpable femoral pulses for potential access sites to deliver the TEVAR.

Diagnostic studies and imaging in symptomatic patients. Recommendation 1: In patients considered at low or intermediate risk for a TAA based on their history and physical examination findings, we suggest chest X-ray as the first radiographic test as it may identify an alternative diagnosis for symptoms and may obviate the need for additional aortic imaging. **Level of recommendation: Grade 2 (Weak), Quality of Evidence: C (Low)**

Recommendation 2: In patients considered at high risk for symptomatic TAA or acute aortic syndrome, we recommend urgent imaging, usually CTA because of its speed and ease of use for preoperative planning. Magnetic resonance angiography (MRA) and transesophageal echocardiography are also adequate for screening to identify thoracic aortic disease but have limited applicability in certain scenarios (discussed further later). **Level of recommendation: Grade 1 (Strong), Quality of Evidence: B (Moderate)**

Implementation remark: The choice of a screening diagnostic study should be based on what is immediately available at that institution.

Practice Statement: If there is a high clinical suspicion for an acute aortic process and the findings on the initial study were normal, a second imaging study may be considered while alternative diagnoses are further explored. **(Ungraded good practice statement)**

Preoperative workup in patients undergoing open surgical and endovascular repair

The preoperative cardiac assessments should follow the general recommendation of the American College of Cardiology/American Heart Association (ACC/AHA) guidelines.²

Emergent or urgent repair. In the presence of thoracic aortic disease with rupture, preoperative imaging should be adequate to evaluate whether the patient's anatomy is amenable to endovascular repair. This typically consists of CTA of the chest, abdomen, and pelvis (from above the clavicles to the femoral heads) to evaluate the proximal and distal seal zones and to evaluate for vascular access options. If coverage of the LSA is planned, CTA through the head and neck is useful to determine the anatomy of the vertebral arteries. In addition, identification of blood or effusions in the thoracic cavity may suggest that the lesion to be treated is acute in nature. CTA may also be useful in the setting of aortoesophageal and aortobronchial fistulas to determine the best way to approach the patient and to determine additional interventions (eg, esophagectomy, lung resection) that may be needed.

Elective repair. Preoperative evaluation in the elective setting consists of cardiac risk stratification and includes weighing of the patient's inherent clinical risk with the risk of surgery. This algorithm is well detailed in the 2014 ACC/AHA guideline on perioperative cardiovascular evaluation and management of patients undergoing noncardiac surgery.²

Assessment of left ventricular function

Recommendation 3: For elective TEVAR cases, we suggest assessment of left ventricular function by transthoracic echocardiography in a patient with dyspnea of unknown origin or in a patient with known congestive heart failure with worsening dyspnea. **Level of recommendation: Grade 2 (Weak), Quality of Evidence: C (Low)**

Additional testing

Practice Statement: Although there are few supporting data, in trying to determine whether a patient with severe COPD is a candidate for open TAA repair or TEVAR, the committee recommends considering pulmonary function testing preoperatively in an attempt to determine baseline pulmonary function, especially if general endotracheal anesthesia is being considered, to determine risk of ventilator dependency postoperatively and ultimately to guide the choice of anesthesia

(general vs local anesthesia). **(Ungraded good practice statement)**

RECOMMENDATIONS FOR IMAGING OF THE DTA BEFORE TEVAR

The goal of this section is to review commonly available aortic imaging modalities and their respective benefits. The most critical findings and clinical suggestions for optimizing image evaluation are presented.

Chest radiography. Chest radiographs are particularly prone to observational and interpretive errors. A study analyzing common diagnostic errors, including aortic disease, in radiology found that 44% of errors occurred in interpreting plain film radiographs, with 49% of these involving chest radiographs.^{54,55}

A large aneurysm alters the normal transverse dimension of the mediastinum and blunts the normal interfaces. Proposed radiographic criteria for a widened mediastinum include a mediastinal width >8 cm or a mediastinal to thoracic width ratio of ≥ 0.25 . Other findings include a left apical “cap,” fluid in the left hemithorax from a ruptured aneurysm, widening of the left or right paraspinal line or right paratracheal stripe, effaced aortic contour, anteroposterior window opacification, tracheal deviation, left mainstem bronchus depression, and deviation of a nasogastric tube to the right of the T4 spinous process.^{54–56}

TAAAs are typically located in the posterior mediastinum and associated with the cervicothoracic sign. This sign is based on the fact that the anterior mediastinum does not extend above the clavicles. Therefore, any mediastinal mass extending above the level of the clavicle with sharply defined borders delineated by an air-soft tissue interface is located in the middle or posterior mediastinum.⁵⁷

Practice Statement: The primary role of chest radiographs in the workup of acute aortic syndromes is the exclusion of other diagnoses. A chest radiograph may be completely normal despite the presence of PAU or IMH. **(Ungraded good practice statement)**

CTA. CTA is the most widely used modality for definitive diagnosis of aortic diseases and has become essential for planning aortic interventions, especially when it is used in conjunction with postacquisition image processing and three-dimensional reconstruction software. This limits radiation exposure and intravenous contrast material use. CTA should also include the femoral and iliac arteries as well as the abdominal aorta in addition to the neck and chest.⁵⁸ Advances in imaging techniques, including electrocardiography-gated CTA, have been demonstrated to decrease the risk of motion artifact in the thoracic aorta.⁵⁹

Recommendation 4: If TEVAR is being considered, we recommend fine-cut (≤ 0.25 mm) CTA of the entire aorta as well as of the iliac and femoral arteries. CTA of the

head and neck is also needed to determine the anatomy of the vertebral arteries.^{60,61} **Level of recommendation: Grade 1 (Strong), Quality of Evidence: A (High)**

Pixel spacing for modern CTA is submillimeter (0.5–0.75 mm), with a typically used slice thickness of around 1 mm, depending on scanner type and manufacturer. Routine computed tomography (CT) scans are often performed in 3- to 5-mm cuts, but three-dimensional planning for endovascular intervention is best done with ≤ 2 -mm cuts.⁶⁰ Given the acquisition method on most modern CTA equipment, images can often be reformatted to thinner cuts if the original data set is still available to do so.

Ideally, CTA should provide aortic opacification at a minimum of ≥ 250 Hounsfield units, ≥ 300 Hounsfield units uniformly being ideal. There is tremendous institutional variation in how this is achieved. There is further variation based on the patient's body habitus and cardiac output and whether a test dose of contrast material vs bolus-tracking software is used. In general, fast injection rates and high concentrations of iodine are the general principles that allow high-quality imaging. A reasonable estimate is that a total of 60 to 140 mL of nonionic iodinated contrast agent can be injected at a rate of 4 to 6 mL/s. This high injection rate necessitates a power injector, preferably with an 18- to 20-gauge intravenous line, usually in the antecubital fossa. Central lines are not desirable as they result in artifacts and make timing of the contrast agent bolus in the thoracic aorta challenging.^{62,63}

Multiplanar reconstructions allow the aorta to be simultaneously visualized in coronal, sagittal, and axial planes. This allows a more nuanced understanding of the location of branches and aortic curvature and a precise identification of seal zones. Centerline reconstructions are used to determine exact distances between branch arteries, and the length of the thoracic aorta can be measured as well. The diameter of the aorta can be precisely determined with centerline measurements as errors of parallax caused by curvature are virtually eliminated.^{63–66}

Recommendation 5: We recommend routine use of three-dimensional centerline reconstruction software for accurate case planning and execution in TEVAR. **Level of recommendation: Grade 1 (Strong), Quality of Evidence: B (Moderate)**

MRA. MRA is not used for routine management of thoracic aortic disease primarily because of the speed and availability of CTA as well as ease of interpretation. However, MRA can provide morphologic and blood flow information without use of iodinated contrast material or radiation exposure and therefore can play an important role in the management of the thoracic aorta.

Traditional methods for non-contrast-enhanced MRA, such as time-of-flight sequences, are being replaced by newer techniques, such as spin-echo and steady-state free precession sequences.⁶⁷ These provide high spatial resolution but are limited in their characterization of

the aortic wall. Artifact can be present from embolization coils or from certain stent graft metallic components.

Contrast-enhanced MRA is typically performed with the administration of gadolinium, which is administered intravenously with use of a power injector, with a dose of 0.1 mmol of gadolinium per kilogram of body weight. Images are acquired with a T1-weighted three-dimensional spoiled gradient-recalled echo sequence, usually during breath-hold. As with CTA, the relationship between contrast material administration and image acquisition is crucial. The source images can be reformatted in multiple planes with maximum intensity projections and volume rendering, and a three-dimensional centerline reconstruction can be generated using the MRA data set.^{68,69}

Recommendation 6: We suggest contrast-enhanced MRA for preoperative planning for patients with severe allergy to iodinated contrast material. **Level of recommendation: Grade 2 (Weak), Quality of Evidence: C (Low)**

Intravascular ultrasound (IVUS). IVUS has become an important adjunct in the endovascular treatment of the thoracic aorta. The presence of thrombus, calcifications, and poor aortic wall integrity can also be seen in the setting of PAUs. IVUS adds significant value in treatment of TAA by reducing intraoperative contrast material volume and radiation use. It also allows precise intraoperative measurement of distances and diameters of the aorta, adding to the preoperative CTA measurements, especially in angulated aortas.^{70,71}

Recommendation 7: We recommend IVUS use in TEVAR for TAA to assess landing zones when cross-sectional imaging is of poor quality, a more detailed evaluation of landing zones or branch vessel origins is needed, or a decrease in contrast material use is desired. **Level of recommendation: Grade 1 (Strong), Quality of Evidence: B (Moderate)**

PERIOPERATIVE MANAGEMENT AND OPERATIVE DECISION-MAKING

Perioperative medical management

Medical management of patients with thoracic aortic disease has been thoroughly described.⁶ This includes control of hypertension, statin therapy/lipid optimization, and smoking cessation. Medical therapy with antihypertensive agents is widely used as a first-line treatment in patients with aortic disease.⁷² Blood pressure control is based on anti-impulse therapy to limit the ventricular ejection force and the aortic wall stress and is especially important in cases of symptomatic aneurysms or acute aortic syndromes. The goal of therapy is to reduce the systolic blood pressure to <20 mm Hg and the heart rate to <60 beats/min when possible before, during, and after TEVAR (see exceptions in recommendations for spinal cord protection). This is usually achieved with intravenous beta blockers (or alpha/beta blockers) as

first-line therapy. For patients who do not respond to or are intolerant of beta blockers, calcium channel blockers or angiotensin-converting enzyme inhibitors or blockers can be used as alternatives or complementaries.⁷³

For patients with dyslipidemia, treatment with a statin to achieve a target low-density lipoprotein cholesterol level of <70 mg/dL is reasonable and may be helpful in controlling the progression of aneurysms.⁷⁴ Counseling for smoking cessation, reduction of environmental tobacco exposure, referral to special programs for cognitive-behavioral therapy, initiation of pharmacotherapy, or, preferably, multimodal management to achieve complete tobacco abstinence is recommended for patients who have active tobacco use or exposure.^{75,76}

Recommendation 8: As hypertension is a modifiable risk factor for the development of aortic aneurysms and is associated with accelerated aortic growth and rupture, we recommend that blood pressure be managed to the adherence of the ACC/AHA guidelines.² **Level of recommendation: Grade 1 (Strong), Quality of Evidence: B (Moderate)**

Recommendation 9: We recommend interventions for smoking cessation in patients with thoracic aortic disease as even passive exposure may increase the risk of aortic rupture. **Level of recommendation: Grade 1 (Strong), Quality of Evidence: A (High)**

Open repair vs TEVAR for TAA

Until recently, surgical management for elective TAA repair required major open surgery, with a significant risk for perioperative morbidity and mortality. Centers of excellence report impressively low mortality and spinal cord ischemia rates in elective cases of 4.8% and 4.6%, respectively.⁷⁷ In tandem, the mortality after open surgical treatment of *ruptured* TAA in highly specialized practices has been reported to be close to 26%.⁷⁸ In contrast, the overall mortality rates in the United States for elective, open repair of TAA is approximately 22%,⁷⁹ highlighting the effect that surgeon and center experience has on overall outcomes of these patients. However, data have consistently demonstrated that TEVAR of isolated TAA is a safe alternative to open surgery and is associated with a substantially lower morbidity and mortality and a shorter hospitalization.^{80,81} Large studies designed to evaluate the long-term (>5 years) outcomes have only recently become available.⁸² Only one small series of thoracic PAU showed a potential benefit to TEVAR because of a similar long-term survival (~50% at 10 years in both groups), with lower morbidity in the TEVAR group, despite being done in patients with a higher number of preoperative comorbidities.⁸³ In addition, only recently has there been an attempt to establish a risk scoring system specifically developed to predict mortality in patients undergoing TEVAR.^{84,85}

A Cochrane review compared thoracic stent grafting to open surgery for TAA and concluded that although stent

Table. Instructions for use of current thoracic devices

Manufacturer	Name	Iliac/femoral diameter, mm	Aortic outer diameter, mm	Proximal landing zone, mm	Distal landing zone, mm
W. L. Gore & Associates ⁹¹	Conformable Thoracic Aortic Graft (c-TAG)	4-8.7, depending on sheath	16-42 ^a	≥20	≥20
Medtronic ⁹²	Valiant Captivia	7.3-8.3, depending on sheath	18-42	≥20	≥20
Cook Medical ⁹³	Zenith Alpha ^b	6.0-7.7, depending on graft size	22-42	≥20	≥20
Bolton ^c Medical ⁹⁴	Relay	7.3-8.7, depending on sheath	19-42	15-25	15-25

^aGore measures inner aortic diameter for graft sizing.
^bCook recalled all Zenith Alpha TEVAR grafts with proximal or distal diameter of 18 to 22 mm and recalled the indication for blunt traumatic aortic injury on March 22, 2017.⁹⁵
^cNow Terumo.

grafting of the thoracic aorta is technically feasible and nonrandomized studies suggest reduction of early adverse outcomes, such as paraplegia, mortality, and hospital stay, high-quality randomized controlled trials assessing clinically relevant outcomes including open conversion, aneurysm exclusion, endoleaks, and late mortality are needed.^{86,87} In addition, although there are no randomized, controlled prospective trials comparing open and endovascular TAA repair and probably never will be, industry-sponsored trials and registry data (Table) suggest clinical equipoise in centers experienced in both techniques.^{77-81,84,85,88-95}

Recommendation 10: In patients who could undergo either technique (within the criteria of the device's instructions for use), we recommend TEVAR as the preferred approach to treat elective DTA aneurysms, given its reduced morbidity and length of stay as well as short-term mortality. **Level of recommendation: Grade 1 (Strong), Quality of Evidence: A (High)**

Indications for repair

TEVAR for TAA. Untreated 6.0-cm TAAs have a 5-year survival of 54%, yielding a 3.7%/y risk for rupture and a risk of dying of ~12%/y.^{25,96} A prospective database of >1600 TAAs and ADs found that an aneurysmal thoracic aorta grows an average of 0.10 cm/y (0.07 cm for the ascending aorta and 0.19 cm for the DTA).^{22,96} In saccular aneurysms, which may have a higher risk of rupture, TEVAR may be justified at a diameter <6.0 cm even though high-quality data are not readily available. Data suggesting that lower thresholds for repair of the DTA in women are also not readily available as aneurysm disease in the thoracic aorta is rarer than in the abdominal aorta. In making treatment recommendations, the patient's overall medical condition and risk profile should be considered. For patients at higher risk for elective repair, a larger aortic diameter threshold may be more appropriate in considering their expected surgical complication rate. In addition, data are lacking regarding rapid aneurysm expansion and what size threshold over time is considered accelerated growth. Therefore, TEVAR based on "rapid expansion" should be individualized and

should take into account the comorbidities of the patients, their expected longevity, and risk factors for a poor outcome after TEVAR.

Recommendation 11: We recommend TEVAR in asymptomatic patients with a descending TAA when the maximum aneurysm diameter exceeds 5.5 cm in "low-risk" patients with favorable aortic anatomy. **Level of recommendation: Grade 1 (Strong), Quality of Evidence: B (Moderate)**

Recommendation 12: We suggest using higher aortic diameter thresholds for TEVAR in patients deemed to have a particularly high risk of death, renal failure, or paraplegia from the procedure, where the benefit of treatment is lower than the risk posed by the natural history of the TAA. **Level of recommendation: Grade 2 (Weak), Quality of Evidence: C (Low)**

TEVAR for IMH and PAU. As mentioned previously, IMH, PAU, and AD may be similar pathologic processes along a spectrum of aortic disease or may occur in isolation, and therefore a discussion of the use of TEVAR for dissection will be undertaken in another SVS document. Patients with asymptomatic, acute IMH may often be managed conservatively with optimal medical therapy in an intensive care setting. According to a contemporary systematic review of 925 patients with IMH, the predictors of complications include persistent pain, hemodynamic instability, maximum aortic diameter >45 mm, IMH wall thickness >10 mm, presence of ulcer-like projections, pleural effusion or hemomediastinum, and periaortic hemorrhage.⁹⁷ The 3-year aorta-related mortality was 5.4% with medical treatment, 23% with open surgery, and 7.1% with endovascular therapy.⁹⁷ Because of the dynamic nature of IMH and its association with AD (AD in evolution), close observation and hypertension control with follow-up imaging are warranted.

Recommendation 13: Because of the dynamic nature of isolated IMH and its known association with AD, we recommend close observation and hypertension control with follow-up imaging as the initial management of patients with asymptomatic IMH. **Level of recommendation: Grade 1 (Strong), Quality of Evidence: B (Moderate)**

Recommendation 14: We recommend TEVAR in patients with IMH or PAU who have persistent symptoms or complications or show evidence of disease progression on follow-up imaging after a period of hypertension control. **Level of recommendation: Grade 1 (Strong), Quality of Evidence: B (Moderate)**

The natural history of and indications for repair in patients with PAUs are controversial, but they have been found in one series to grow 2 mm/y in their maximal aortic size and length while growing an average of only 1.2 mm/y in depth.⁹⁸ The presence of symptoms, an associated IMH, and an increase in pleural effusion appear to be risk factors for complications.^{83,99} Treatment with TEVAR is indicated for patients who are symptomatic despite best medical therapy or have an increase in pleural effusion. The threshold for intervention for asymptomatic patients is also controversial. According to one study, PAU depth >10 mm and diameter >20 mm are risk factors for progressive disease.⁹⁹

Recommendation 15: We suggest TEVAR in selected cases of asymptomatic PAU in patients who have at-risk characteristics for growth or rupture. **Level of recommendation: Grade 2 (Weak), Quality of Evidence: B (Moderate)**

Practice Statement: In the absence of clear and widely accepted parameters, the decision to intervene in asymptomatic patients with IMH and PAUs should be individualized. Asymptomatic patients treated for PAUs in the setting of a maximal aortic diameter <5.5 cm or with PAUs <10 mm deep or <20 mm in diameter need further study. **(Ungraded good practice statement)**

TEVAR for infected TAAs. Whereas the use of TEVAR to treat infected aortic diseases has often been reported in single or small case series, there are no convincing long-term data to fully support it as a definitive therapy. Although TEVAR can be effective when it is used to temporize ruptured infected TAA or life-threatening fistula with a hollow organ (ie, aorto-esophageal and aortobronchial fistulas), patients with this clinical presentation have high morbidity and mortality regardless of the subsequent management strategy.¹⁰⁰⁻¹⁰³ TEVAR may offer a more durable repair if the endograft is pretreated with antibiotics, such as rifampin, but there are limited data in widely disparate clinical scenarios.^{100,104,105}

Recommendation 16: We suggest TEVAR for symptomatic mycotic/infected TAAs as a temporizing measure, but data demonstrating long-term benefit are lacking. **Level of recommendation: Grade 2 (Weak), Quality of Evidence: C (Low)**

Choice of anesthetic and monitoring techniques

Anesthesia. It is technically feasible to perform TEVAR procedures percutaneously under monitored anesthesia care with local anesthesia.¹⁰⁶ Among other benefits of avoiding general anesthesia, local anesthesia may

theoretically allow neurologic evaluation of the patient's lower extremities.¹⁰⁷

Arterial lines, large-bore venous access, and cerebrospinal fluid (CSF) drains are placed before TEVAR. The necessity for each of these depends on the complexity of the repair, the risk of spinal cord ischemia, the planned duration of the procedure, and the likelihood of significant blood loss. Other adjunctive techniques performed during TEVAR, such as somatosensory and motor evoked potential monitoring, rapid arterial pacing, or pharmacologically induced hypotension, may be used as well.

Practice Statement: Comparative, high-quality data regarding the use of local anesthesia vs general anesthesia during the performance of TEVAR are lacking, and it is typically physician or hospital dependent. **(Ungraded good practice statement)**

Spinal cord protection. Spinal cord injury (SCI) can be a devastating complication that has a profound impact on the benefit of the procedure, given the higher risk of mortality if it occurs. Although up to 70% of patients will have some functional improvement after suffering SCI, only 38% are reported to return to normal function.¹⁰⁸ Those patients who do not have functional improvement have an abysmal prognosis, with mortality as high as 75% at 1 year.^{108,109}

Given these poor results after SCI, a number of prevention strategies have been employed to mitigate risk, including maintenance of LSA and hypogastric patency,¹¹⁰ staging strategies for long-segment aortic coverage,¹¹¹ prophylactic CSF drainage, anemia prevention, permissive hypertension, steroid and naloxone therapy,¹¹² burst suppression, permissive hypothermia, and hyperoxygenation therapy. Most successful centers employ a multimodal and systematic approach to SCI prevention, with detailed protocols on management of spinal drains, multidisciplinary coordination, and rescue procedures for those presenting with delayed SCI.¹¹³

Techniques for spinal cord protection after thoracic aortic surgery have evolved significantly during the last four decades.⁹⁶ Paraplegia after TEVAR limited to the DTA is uncommon (<5%) compared with open aneurysm repair, despite the observation that TEVAR invariably covers intercostal branches. This highlights the fact that the cause of SCI after open and endovascular repair is multifactorial and not simply related to cessation of intercostal artery perfusion. However, there are data demonstrating that increased aortic coverage leads to a higher risk of SCI, supporting the notion that the intercostal arteries are in fact an important source of spinal cord perfusion.¹¹⁴ Of note, protocols are published describing the complex interaction between mean arterial pressure and spinal cord pressure.¹¹⁵

Somatosensory and motor evoked potentials permit continuous monitoring of the spinal cord's function, assist in the early detection of SCI, and are popular techniques used in high-risk cases during open TAA repair or

when patients are undergoing branched or fenestrated endovascular aneurysm repair (EVAR).^{116,117} They are rarely used in the setting of simple TEVAR.

Indications for prophylactic CSF drainage catheter placement during TEVAR are controversial, and CSF drains should be used as only one part of a multimodal protocol to reduce the risk of SCI. Some authors recommend selective CSF drain placement for only high-risk patients, whereas others perform CSF drain placement preoperatively routinely.^{113,117-119} Risk factors for SCI after TEVAR include length of aortic coverage (especially when it is in excess of 15 cm of the DTA) and existence of infrarenal aortic disease.¹²⁰ In addition to these anatomic risk factors, chronic renal failure may also be an important risk factor.¹²¹ According to one systematic review, the incidence of SCI after TEVAR with and without prophylactic CSF drain placement was 3.2% and 3.5%, respectively.¹²² In contrast, a 2016 systematic review of the use of lumbar drains in open repair and TEVAR (including three randomized trials) concluded that spinal drains prevent early SCI with an OR of 0.48 (95% CI, 0.30-0.76; $P = .002$), absolute risk reduction of 4.5%, and number needed to treat of 23 in favor of CSF drainage.¹²³

There are many differences in institutional protocols for CSF drain management. They vary widely from where to level the drain (earlobe or spinal exit site), draining to a target pressure vs to a target volume, what the baseline pressure should be and the units (centimeters of water or millimeters of mercury), and the maximum amount of fluid that should be drained (per hour, per 4 hours, or per day) to avoid intracranial bleeding or herniation.

Other adjunctive methods of SCI risk reduction include the routine use of naloxone and steroids, avoidance of long-acting narcotics, and hemoglobin management strategies, which vary across centers.^{113,124} An often-used hemoglobin target is >10 mg/dL, especially for patients who have symptoms of SCI. Rescue protocols also exist, which include a further increase in systemic blood pressure to >100 mm Hg, a drop in the CSF drain pressure (often 5 mm Hg or 7 mm Hg), transfusion to a target hemoglobin level of >10 mg/dL, and the use of steroids.¹²⁵

Recommendation 17: We recommend increasing perfusion pressure through controlled hypertension (mean arterial pressure >90 mm Hg) as a component of a spinal cord protection protocol in patients at high risk of SCI because of extensive coverage length (>15 cm), poor hypogastric perfusion (occluded or significantly stenosed hypogastric arteries), or coverage of important collaterals (subclavian/hypogastric arteries).
Level of recommendation: Grade 1 (Strong), Quality of Evidence: B (Moderate)

Recommendation 18: We recommend prophylactic CSF drainage for SCI protection in TEVAR cases that are deemed high risk (covering extensive length of descending aorta; previous aortic coverage, including EVAR and

open AAA repair; compromised pelvic perfusion with diseased or occluded common or internal iliac arteries; diseased or occluded vertebral arteries; planned LSA coverage; or deemed high risk by the operating surgeon).

Level of recommendation: Grade 1 (Strong), Quality of Evidence: B (Moderate)

Management of the LSA and vertebrobasilar system

An adequate proximal landing zone requires coverage of the LSA in 26% to 40% of patients undergoing TEVAR.^{109,126} In the first U.S. TEVAR regulatory trial,⁸⁰ all patients underwent prophylactic LSA revascularization before TEVAR if the operative plan called for LSA coverage. Guidelines on LSA revascularization were published in 2009 by the SVS,¹²⁷ yet there remains variability in this practice with continued debate on the indications for revascularization. Some surgeons perform revascularization routinely, some selectively, and some perform LSA revascularization only if symptoms occur after TEVAR.^{127,128} There are four major concerns with coverage of the LSA: spinal cord ischemia, stroke, arm ischemia, and vertebrobasilar ischemia.

Spinal cord ischemia. Understanding the anatomy of the LSA branches and the critical anterior spinal artery is important as the LSA provides inflow into the anterior spinal artery through multiple pathways. There is general consensus that patients with focal disease and who are treated with shorter (≤ 15 cm) stent graft lengths are at lower risk for spinal cord ischemia.^{114,126} Data from the European Collaborators on Stent/graft Techniques for Aortic Aneurysm Repair (EUROSTAR) registry, one of the largest series with specific attention to TEVAR and anatomy, demonstrated rates of spinal cord ischemia and stroke as high as 8.4% when there was LSA coverage without revascularization compared with 0% in those patients who underwent prophylactic LSA revascularization ($P = .049$).¹⁰⁹

After reports of lower spinal cord ischemia rates in experimental, sequential, and progressive embolization of spinal vessels in animal models,¹²⁹ many have advocated for staging the coverage of large segments of the aorta to allow preconditioning or even purposeful spinal artery embolization before extensive TEVAR.¹³⁰

Stroke. The incidence of stroke during and identified after TEVAR for TAA generally ranges from 3.2% to 6.2%,¹³¹ and it may be lethal in one third of these cases.¹³² However, this range may vary according to the indication for TEVAR. A meta-analysis of the Cook-sponsored multicenter trials demonstrated even lower rates in certain populations of patients, with a 30-day stroke rate of 0% in the 56 patients treated for PAU. It was also only 2.4% in the 329 patients treated for TAA.¹³³

There is published consensus that coverage of the LSA is associated with higher risk of stroke with TEVAR, despite the fact that the stroke may not always be in the posterior circulation. A series of 285 TEVAR patients showed that coverage of the LSA was associated with

an 11% stroke rate compared with 3% when it was not covered.¹³⁴ The current debate centers on what interventions may reduce this risk. Approaches to prevent stroke include careful manipulation of wires and catheters near the carotid vessels, denitrogenation devices, accurate imaging and positioning of devices, routine LSA revascularization, and thorough understanding of each patient's arch and cerebral anatomy. A systematic review of 27 studies found a stroke rate of 5.6% associated with LSA coverage and a reduction to 3.1% with LSA revascularization (not statistically significant).¹³⁵ In the Medtronic Outcomes of Thoracic Endovascular Repair (MOTHER) registry of 1010 TEVAR patients, stroke was 2.2% without coverage of LSA, 9.1% with coverage and no revascularization, and 5.1% with LSA coverage and revascularization, supporting routine LSA revascularization.¹³⁶ The largest systematic review and meta-analysis support these findings. A review¹³⁷ published in 2017 evaluated the incidence of stroke in 2594 patients treated with TEVAR and found the incidence in patients when the LSA was uncovered to be 3.2% (95% CI, 1.0-6.5). When the LSA was covered but revascularized, the stroke rate was 5.3% (95% CI, 2.6-8.6) compared with 8.0% (95% CI, 4.1-12.9) when the vessel was covered without revascularization. Despite these data, selective LSA revascularization strategies are not embraced by some because of concerns for prolonging the procedure, complications of revascularization operations, and a perception that patients at elevated risk for subclavian artery ischemia can be identified ahead of time.¹³⁸

There are two scenarios in which LSA revascularization should always be considered to reduce perioperative stroke, even in "selective" approaches. Most concerning is when a nonrevascularized vertebral artery ends in the posterior inferior cerebellar artery, which would risk causing inadequate flow through the circle of Willis into the posterior cerebral circulation.¹³⁹ In addition, with a dominant left vertebral artery (66%-75% of patients) in the presence of an absent, atretic, or diseased right vertebral artery, nonrevascularization of the LSA increases the risk for posterior cerebral ischemia.

Arm ischemia and vertebrobasilar insufficiency. Left arm ischemia symptoms may range from none to a frankly threatened limb. Special consideration should be given to LSA revascularization and left arm perfusion for patients at risk of coronary ischemia due to a prior left internal mammary artery (LIMA) to left anterior descending artery coronary bypass graft as well as for those with existing arteriovenous fistulas in the left arm. Although flow reversal in the vertebral artery is common after LSA coverage, most patients are asymptomatic from this hemodynamic perturbation. However, some may suffer from subclavian steal syndrome and symptomatic vertebrobasilar insufficiency manifested as syncope, diplopia, or vertigo. In one series, upper extremity ischemia occurred 12% to 20% of the time after LSA

coverage, although <40% of patients with symptoms of arm ischemia underwent delayed LSA revascularization.^{140,141} Because presentation of ischemic symptoms of the arm is often delayed, with time to presentation ranging from 2 days to 26 months, revascularization can typically be addressed on a less urgent basis.

Additional considerations. The Knowledge and Encounter Research Unit performed a systematic literature review and meta-analysis relating to the effect of LSA coverage on the morbidity and mortality of patients undergoing TEVAR.¹⁴² This analysis found that coverage of the LSA without revascularization compared with coverage with revascularization was associated with trends toward increased risk of spinal cord ischemia (OR, 2.69; 95% CI, 0.75-9.68), anterior circulation stroke (OR, 2.58; 95% CI, 0.82-8.09), arm ischemia (OR, 47.7; 95% CI, 9.9-229.3), and vertebrobasilar ischemia (OR, 10.8; 95% CI, 3.17-36.7). More data have been published since 2009, such as a large single-center series in which the combined stroke, paraplegia, and death rate comparing LSA revascularization with coverage alone is a striking 0% vs 27.9% ($P < .001$).¹⁴³ Additional findings from a 2017 report revealed a higher 30-day stroke rate in cases in which the LSA was covered compared with when it was revascularized (14.3% vs 1.9%, respectively; $P = .02$).¹³⁷ The consistent nature of these findings (including another meta-analysis¹⁴⁴) supports elective LSA revascularization to lower the risk of stroke and paraplegia. Certain limitations persist in the observational nature of these data, including heterogeneous patients, infrequent and inconsistently defined outcomes of interest, and underpowered studies. Large databases often exclude specific populations, such as trauma patients, or do not capture anatomic variables or staged LSA revascularization.¹⁴⁵

LSA surgical revascularization is typically performed with a left carotid-subclavian bypass, subclavian to carotid transposition, or carotid-axillary bypass, with similar patency (84%-96% at 5 years)^{128,146,147} for each technique. On occasion, when the left vertebral artery arises directly from the arch or is very proximal on the LSA, a separate vertebral transposition or bypass is necessary. A transposition is relatively contraindicated when there is coronary artery bypass from the LIMA as this would cause myocardial ischemia during subclavian artery clamping and, potentially, difficulties in mobilizing the LSA cephalad if it is tethered by the LIMA graft.

Complications of LSA revascularization, specifically in the setting of TEVAR, have been studied. From the systematic review, the overall incidence of phrenic nerve injury was low at 4.4% (95% CI, 1.6%-12.20%).¹⁴² Woo et al¹⁴¹ examined 42 patients requiring LSA revascularization (5 transpositions, 37 bypasses), and only 1 patient (2.4%) developed a phrenic nerve palsy. Zamor et al¹²⁸ described 23 patients who underwent LSA revascularization (21 transpositions, 2 bypasses) before TEVAR and had 2 (8.7%) occurrences of vocal cord paralysis, one of which

resolved spontaneously. Wound complications, such as hematoma, lymphatic leak, and dissection, have also been reported.¹⁴⁸ A series of 101 LSA revascularizations had a relatively high rate of permanent nerve injuries (9%) along with a 6% lymph leak rate, requiring dietary modification alone.¹⁴⁹ Despite these complications, the series reported only a 2% ischemic stroke rate and 0% SCI after TEVAR.

Despite a net benefit of reduction in SCI and stroke,¹⁵⁰ these complications certainly compromise the effectiveness of TEVAR. Off-label and emerging technologies offer the potential to reduce the complications of LSA surgical revascularization. For well over a decade, various techniques have been described for retrograde in situ graft fenestration and stenting, in which the TEVAR graft is punctured with a needle or laser and dilated and a covered stent is inserted to bridge from the fenestration to the LSA,¹⁵¹⁻¹⁵³ although the impact of these techniques on the durability of the graft is unknown. Chimney or double-barrel stents have also been described, which involve deployment of a covered stent in the LSA concomitantly with a thoracic stent graft, preserving flow into the LSA.^{154,155} More recently, TEVAR grafts with a branch for the LSA have been developed and are actively being evaluated in clinical trials.^{156,157} Industry-sponsored trials of fenestrated and branched distal aortic arch endografts as well as multiple case reports of homemade or physician-modified endografts will likely change the approach to revascularization of the LSA in the future.

Recommendation 19: For elective TEVAR of a TAA where coverage of the LSA is necessary for adequate stent graft seal, we suggest preoperative or concomitant LSA revascularization. **Level of recommendation: Grade 1 (Strong), Quality of Evidence: B (Moderate)**

Recommendation 20: For patients in whom the anatomy to be treated compromises perfusion to vital structures, we recommend LSA revascularization. **Level of recommendation: Grade 1 (Strong), Quality of Evidence: B (Moderate)**

Examples of these circumstances include the following:

Presence of a patent LIMA to coronary artery bypass graft
Termination of the left vertebral artery into the posterior inferior cerebellar artery

Absent, atretic, or occluded right vertebral artery

Patent left arm arteriovenous shunt for dialysis

Prior infrarenal aortic operation or EVAR with previously ligated or covered lumbar and middle sacral arteries

Planned extensive coverage (≥ 15 cm) of the DTA

Hypogastric artery occlusion or significant occlusive disease

Presence of aneurysm disease in the young patient, for whom future therapy involving the distal thoracic aorta may be necessary

Recommendation 21: For patients with acute thoracic emergencies, for whom TEVAR is required urgently and coverage of the LSA is necessary, it is suggested that

revascularization be individualized and addressed on the basis of the patient's anatomy and urgency of the procedure. **Level of recommendation: Grade 2 (Weak), Quality of Evidence: B (Moderate)**

Renal protection strategies for TEVAR

Acute kidney injury (AKI) occurring during hospitalization or after surgery has one of the highest risks of predicting mortality, especially if the AKI progresses to dialysis. When AKI occurs after TEVAR (~10%-15%), it increases the OR of death to almost 10 even without a need for dialysis.^{158,159} Many risk factors for AKI are associated with patients undergoing TEVAR (advanced age, chronic renal failure, diabetes, congestive heart failure, exposure to injectable contrast dye, blood loss, major surgery) and possibly embolic injury from endovascular manipulation within the aorta.

Importantly, contrast-induced nephropathy is the third leading cause of AKI in hospitalized patients. Although it is plagued with inconsistent definitions in the literature, its incidence varies between 5% and 25%. Factors consistently shown to increase risk for contrast-induced nephropathy include age, diabetes, previous renal disease, and escalating doses of contrast material.¹⁵⁹⁻¹⁶¹

Strategies reported to prevent contrast-induced nephropathy are also marred by inconsistent reporting standards and patient risk factors.^{160,161} These include use of IVUS, minimizing the amount of contrast material used during the operation, prehydration with normal saline (effectively increasing the volume of distribution of intravascular contrast material), and use of nonionic, iso-osmolar contrast agents.^{162,163} Research on pretreatment with statins is evolving.¹⁶⁴

Recommendation 22: We recommend preprocedural TEVAR planning to include sizing and landing sites before the case to minimize procedural contrast material use. If available, intraoperative CTA overlay technology and IVUS should be used to minimize use of contrast material. **Level of recommendation: Grade 1 (Strong), Quality of Evidence: B (Moderate)**

Recommendation 23: We recommend nonionic, hypo-osmolar contrast material with attempts at minimizing intra-arterial contrast agent use, especially in patients at high risk for contrast-induced nephropathy. **Level of recommendation: Grade 1 (Strong), Quality of Evidence: B (Moderate)**

Recommendation 24: Depending on the patient's corporal density and the capacity of the X-ray equipment available, we suggest diluting contrast material in the power injector when possible (typically to 50% or 70%). Adjustments in injection volume and time (faster injection of smaller doses) can usually compensate when additional visibility is required. **Level of recommendation: Grade 2 (Weak), Quality of Evidence: C (Low)**

Recommendation 25: We suggest the use of on-table mapping software options on fixed-imaging X-ray systems, such as roadmapping and CT fusion or overlay

reference, to aid in locating target landing sites and to minimize need for repeated injections. If available, CT overlay capability is extremely useful, especially in cases in which location and cannulation of branches will be needed. **Level of recommendation: Grade 2 (Weak), Quality of Evidence: B (Moderate)**

Implementation remark

In high-risk patients, placing and leaving wires, catheters, or sheaths in aortic branches can mark the location of target branches and minimize the need for repeated contrast angiography. A marker catheter may be inserted through a small-diameter left brachial artery sheath, for example, to mark the location of the LSA, or a wire or catheter placed in the CA to mark its location regardless of aortic or thoracic motion. This strategy can also allow bailout techniques in case of branch coverage.

Recommendation 26: To decrease the risk of atheroembolization, we recommend minimizing intra-aortic wire, catheter, and endograft manipulation in the aortic arch and at or above the visceral/renal arteries, especially in patients with significant aortic atheromatous disease or thrombus. **Level of recommendation: Grade 1 (Strong), Quality of Evidence: B (Moderate)**

Recommendation 27: We recommend minimizing the dwelling time of large or occlusive femoral artery sheaths to decrease the risk of spinal cord ischemia and lower extremity ischemia that can lead to postoperative compartment syndrome or rhabdomyolysis. In cases in which a large sheath must be left in place for a prolonged time, it can be withdrawn into the external iliac artery to allow antegrade flow into the ipsilateral internal iliac artery. Meticulous postoperative vigilance to detect inadequate lower extremity perfusion or compartment syndrome should be routine. **Level of recommendation: Grade 1 (Strong), Quality of Evidence: B (Moderate)**

Recommendation for coverage or occlusion of the CA during TEVAR

TAA treated by TEVAR may require coverage of the CA in about 4% to 6% of cases.^{89,165} This can add 1 to 2.5 cm or more of aorta to obtain a distal seal. In addition, the CA is stenotic in approximately 20% of patients, most of these being asymptomatic, presumably because of collateral mesenteric flow.¹⁶⁶⁻¹⁶⁸ Collaterals generally arise from the superior mesenteric artery (SMA) and can be evaluated by selective SMA arteriography. Collateral pathways can also be identified using high-resolution CTA reconstructions (ideally 1-mm cuts or smaller, 16-slice or greater), and the anatomic correlations have been well described.¹⁶⁹ In 94 cases of celiac stenosis (13 with aberrant hepatic artery origins), 95% had collateral flow from the pancreaticoduodenal and 75% from the dorsal pancreatic arteries. These were similar in cases in which the hepatic arteries originated

from the SMA (92% and 77%, respectively). In addition, flow from the left and right gastric arteries to the hepatic arteries has been documented.¹⁶⁹ Examples of CTA-relevant findings that are important to note if CA coverage is planned include significant stenosis of the SMA, occluded inferior mesenteric artery, large post-stenotic dilation of the CA, and inability to visualize the pancreaticoduodenal or dorsal pancreatic branches. CTA alone may predict ischemia after CA coverage and the need for CA revascularization through open (traditional open surgical management) or endovascular interventions (such as parallel ["snorkel"] stents or fenestrations, given appropriate investigational device exemption and local experience). However, CTA does not demonstrate dynamic flow and has been proved to be incorrect as a single imaging modality in predicting safe coverage of the CA after TEVAR by some authors.^{170,171}

If CA coverage occurs without revascularization, a high degree of suspicion for ischemic complications should be maintained postoperatively. Furthermore, ischemia symptoms can range from mild reversible abdominal pain to mild liver enzyme elevation to lethal ischemic injury of the foregut, spleen, or liver. Balloon occlusion has been reported by some in a small number of cases (n = 5 each) to determine suitability for CA coverage, with unclear sensitivity and specificity.¹⁷² Thus, although it is reasonable in cases in which the results from mesenteric angiography are equivocal, no strong recommendation can be made.

The largest series of CA coverage included only 31 cases. The protocol was to evaluate CTA for collaterals and, if absent, to perform SMA angiography to evaluate for retrograde flow into the celiac branches. If absent, the CA was occluded with a balloon and the imaging repeated. Notably, the authors aggressively and pre-emptively treated SMA stenosis or cases in which partial SMA coverage occurred during TEVAR (39% of cases) with balloon-expandable stents. They documented one case of lethal hepatic ischemia (despite subsequent open bypass), one case of acalculous cholecystitis, and one case of sigmoid colon ischemia thought to be embolic.¹⁷³ Another study evaluated 18 TEVAR cases using only angiography (no balloon occlusion) before CA coverage. Two patients had documented mesenteric ischemia after CA coverage. One patient had self-limited abdominal pain and two others had elevated white blood cell counts, also self-limited. No elevation in the liver or pancreatic enzymes occurred after TEVAR.^{174,175} In another series, CA coverage led to a delayed presentation of iatrogenic chronic mesenteric ischemia despite only "encroaching" on the CA and a widely patent SMA.¹⁷⁶

If the seal zone includes the CA orifice, an appropriately sized endograft alone should occlude the origin of the CA, obviating the need for embolization. If it is absolutely needed, CA embolization should be done carefully and

sparingly to avoid inadvertent extension of the embolic material into the common CA trunk and risking foregut ischemia. In cases of TEVAR covering the CA, vigilant postoperative clinical examination and serial laboratory studies should follow the early post-TEVAR period to detect and to address foregut and hepatic ischemia as early as possible to avoid morbid and lethal complications.

Practice Statement: Although there are few high-quality data, we suggest dedicated SMA angiography through the SMA or CA with adequate imaging of the entire SMA and CA mesenteric collateral system to precede TEVAR with intended or high risk for CA coverage. **(Ungraded good policy statement)**

Recommendation 28: We recommend pre-emptive SMA stenting with a balloon-expandable stent in cases of >50% stenosis of the SMA in the following conditions: before or after CA coverage or encroachment, with TEVAR that is encroaching on the SMA origin, or in any patient otherwise considered at high risk for post-TEVAR mesenteric ischemia. **Level of recommendation: Grade 1 (Strong), Quality of Evidence: B (Moderate)**

Recommendation 29: In anticipation of high risk for CA territory ischemia (nonvisualization of CA collateral branches by CTA or dedicated SMA angiography), we recommend open or endovascular revascularization of the CA before TEVAR. **Level of recommendation: Grade 1 (Strong), Quality of Evidence: B (Moderate)**

Practice Statement: Maintain meticulous vigilance for signs and symptoms of mesenteric and hepatic ischemia early after CA coverage. **(Ungraded good practice statement)**

Recommendation for access during TEVAR

Importantly, access-related issues remain a common source of morbidity after TEVAR, although these complications are certainly decreasing with the increasing lubricity and decreasing diameter of device delivery systems. In several early multicenter, industry-sponsored trials, procedural failures ranged from 0.5% to 2% and were almost all secondary to the inability to advance the device through inadequate iliac arterial systems.^{80,89,90} There has been an effort recently to decrease the size of the sheaths and to improve the trackability of TEVAR delivery systems. Nonetheless, a study of a lower profile device (sheath sizes 16F-20F) still had a 2% failure to implant secondary to access issues.¹⁷⁷

Depending on the size of the graft to be implanted, the outer diameter of delivery systems can be larger than 24F with some devices. One French is approximately $\frac{1}{3}$ mm; thus, a 24F outer diameter sheath is 8 mm in diameter. In the setting of normal vessels with little tortuosity, the vessel may stretch and allow delivery of a sheath that is larger than the actual inner diameter of the vessel. However, increasing tortuosity or calcification can reduce the

effective inner diameter of the delivery vessel, leading to the need for adjunctive methods of device delivery.

Several adjunctive measures can facilitate access in patients with small iliac vessels, including the use of more proximal arteries as well as open or endovascular conduits.

Femoral access. Traditional open femoral exposure during TEVAR involves exposing the common femoral artery at the level of the inguinal ligament and establishing sites for proximal and distal control. Unlike endovascular AAA repair, in which medium- to large-diameter sheaths are placed in both groins, TEVAR can usually be accomplished through one femoral artery exposure with the other reserved for diagnostic imaging through a 5F or 6F percutaneously placed sheath, if needed. When open femoral artery exposure is performed, a transverse or oblique skin incision is favored over the vertical approach in the groin as it is associated with fewer wound complications. Wound complication rates (excluding hematomas) after endovascular repair with a vertical incision are as high as 18%,¹⁷⁸ whereas several studies with oblique incisions have reported virtually no infectious wound complications.^{179,180}

Percutaneous access of the common femoral artery for TEVAR is also a common approach to access and is increasing in frequency as surgeons become more comfortable with it.¹⁸¹ A discussion of the pitfalls and merits of individual closure devices is beyond the scope of this document. However, several techniques have been described for identification of the femoral artery, including access through a small transverse incision^{182,183} and ultrasound guidance,^{184,185} with reported success rates ranging from 92% to 96%. Ultrasound guidance has become a standard component of percutaneous endovascular access at most institutions as it helps the operator identify and avoid anatomic factors that could lead to failure of closure, such as coursing through the inguinal ligament or calcium on the anterior wall of the artery. One study reported that the use of ultrasound led to a 10-fold increase in successful percutaneous EVAR procedures compared with those performed without ultrasound ($P = .03$).¹⁸⁶

A meta-analysis performed of 3606 percutaneous arterial access attempts for endovascular aortic repair included 469 percutaneous TEVAR procedures. The overall technical success rate was 94% per arterial access and the groin complication rate was 3.6%, with only 1.6% of patients requiring open repair of the groin.¹⁸⁷ The most common complication was groin hematoma (1.8%), followed by pseudoaneurysm (0.7%). Factors that improved successful percutaneous access included ultrasound guidance (96.4% with ultrasound vs 93.5% without; $P = .02$) and a sheath size <20F (94.2% <20F vs 88.7% ≥ 20 F; $P < .001$).¹⁸⁷ Other anatomic factors that have been associated with improved success with a percutaneous approach include a >1-cm segment of mid common femoral artery without anterior calcification,

absence of severe scarring in the groin, native arterial access (as opposed to access in graft material), and access vessel diameter >5 mm.^{182,184,186,187} Percutaneous femoral access has a safety profile that is comparable to that of open femoral access in anatomically appropriate patients, and both approaches are appropriate for TEVAR, even in the obese.¹⁸⁸

Recommendation 30: If an open approach for access is used, we recommend transverse or oblique incisions in performing open femoral access for TEVAR. **Level of recommendation: Grade 1 (Strong), Quality of Evidence: B (Moderate)**

Recommendation 31: We recommend using ultrasound guidance for percutaneous access to improve procedural success and to decrease the rate of major complications. **Level of recommendation: Grade 1 (Strong), Quality of Evidence: B (Moderate)**

Recommendation 32: We recommend that percutaneous access for TEVAR is safe and an acceptable alternative to open common femoral artery exposure if certain anatomic criteria are met (eg, diameter of common femoral artery, lack of front wall calcium). **Level of recommendation: Grade 1 (Strong), Quality of Evidence: B (Moderate)**

Iliac or aortic access. Multiple industry-sponsored trials of TEVAR have shown that the sizes of the common and external iliac arteries remain a barrier to device delivery in some patients. Atherosclerotic occlusive disease can be treated with balloon angioplasty or use of the Dotter technique with serially larger balloons and dilators to facilitate transfemoral delivery of a device, but it should be performed carefully with low-pressure inflations starting with a small balloon to avoid iliac rupture.

Data from the early Food and Drug Administration and prospective company-sponsored investigational device exemption trials showed that iliac conduits were used in 15% to 21% of patients.^{80,90,189} Improvement in the profile and size of delivery systems has decreased this number significantly. An industry-sponsored trial of a TEVAR device with delivery systems that range from 16F to 20F required an iliac conduit in only one (0.9%) patient.¹⁷⁷ This low number was aided by strict exclusion criteria that included iliac tortuosity, calcification, occlusive disease, and an inner wall diameter that was not adequate for the required sheath diameter.¹⁷⁷

A review of the National Surgical Quality Improvement Program database showed that conduits were more likely to be performed in women (15.7% female vs 5.8% male; $P < .001$), patients who are current smokers, and patients with a previous coronary intervention.¹⁹⁰ The decision to use an iliac conduit should be made during the planning phase of the case as attempts to deliver a large device through clearly inadequate iliac vessels can lead to prolonged operative times and increase the risk of hemorrhage and death secondary to iliac disruption. The anatomic factors that increase the need for conduits

include tortuous iliac arteries, heavy calcification, and small vessel size relative to the chosen device.

An open surgical iliac conduit is usually performed with a retroperitoneal exposure of the common iliac artery or distal aorta through an oblique incision in the lower quadrant of the abdomen. The choice of common iliac artery vs the aorta should be based on CTA findings, such as calcification and artery size. A 10-mm prosthetic conduit is best used because it will facilitate delivery of all currently available stent graft systems. The anastomosis can be performed in an end-to-side or end-to-end fashion. The conduit can be tunneled to the groin or brought subcutaneously through the abdomen so that it creates an angle that allows straight delivery. At the completion of the procedure, the conduit can be oversewn near the anastomosis. Alternatively, the distal end can be anastomosed to the common femoral artery to bypass an occluded or injured external iliac artery while also providing an easy conduit in the future if further interventions are necessary.¹⁹¹

Direct puncture of the iliac artery and the aorta has also been described with avoidance of the need for a conduit. Most often, these arteriotomies are closed primarily, especially in the absence of extensive atherosclerotic occlusive disease.¹⁹²

Recommendation 33: We recommend the use of iliac conduits or direct iliac or aortic punctures for TEVAR delivery to facilitate access in patients with small (relative to the chosen device), tortuous, or calcified iliac vessels. The decision to perform a conduit should be made in the preoperative setting, when possible. **Level of recommendation: Grade 1 (Strong), Quality of Evidence: B (Moderate)**

Endoconduit. In an effort to avoid the potential increased morbidity and operative time associated with a retroperitoneal exposure of the common iliac vessels or distal aorta, the use of angioplasty and stenting as an endoconduit has been reported.¹⁹² In general, a 10-mm self-expanding covered stent graft is placed, but others have advocated placing an EVAR limb with at least a 12-mm distal diameter as an endoconduit. This can then be dilated with balloon angioplasty to an appropriate size. Some authors have advocated for intentional rupture of the iliac vessel within the stent grafted portion, given that the vessel wall or atherosclerosis can continue to impede device delivery even after endoconduit placement, especially when there is bulky calcific disease.¹⁹³

In a retrospective series comparing open iliac conduit with endoconduit including 39 patients (23 open conduits, 16 endoconduits), the iliofemoral complication rate was 20% for the entire cohort, but it was lower in the endoconduit group compared with the open conduit (12.5% vs 26.1%). This was not statistically different secondary to small numbers of patients.¹⁹⁴ Other published experiences with this technique include small cohorts of patients.¹⁹⁵⁻¹⁹⁷

Recommendation 34: We suggest that endoconduits to facilitate access for TEVAR are an acceptable alternative to an open iliac conduit in some cases, but few data comparing them with an iliac conduit or long-term data describing their outcomes over time are available. **Level of recommendation: Grade 2 (Weak), Quality of Evidence: C (Low)**

Carotid-axillary access. Use of the carotid and axillary arteries to deliver and to deploy thoracic stent grafts has been described,¹⁹⁸ but these cases have been reserved for extreme situations in which access cannot be obtained from the lower extremities because of iliac or distal aortic occlusion. An approach to the DTA from the arch vessels means that the stent graft will be deployed in an inverted fashion (unless predeployed and reinserted into the sheath, which would be an off-label use of the device) and may be associated with an increased risk of neurologic complications due to the wires and sheaths crossing the arch of the aorta.

More commonly, the brachial or axillary arteries are used to facilitate access from below by the so-called body floss technique with a brachiofemoral or axillofemoral wire, in which a wire is passed from the right brachial or axillary artery and brought out the ipsilateral groin, typically by snaring the wire. With tension on both ends, this technique can allow delivery of a stiff device through a tortuous and otherwise impassable aorta. Care should be taken not to injure the origins of the brachiocephalic vessels with the stiff wire passing through them. A long sheath (typically 5F or 6F) should be used to protect these vessels, and it can be used to cover the tip of the delivery system on the stent graft and to facilitate delivery using a “push-pull” technique.

Practice Statement: Brachiocephalic access for TEVAR device delivery may be acceptable in situations in which transfemoral or iliac access is not available. However, more data are required to determine whether carotid-axillary artery access for delivery of a thoracic endograft is associated with increased complications. **(Ungraded good practice statement)**

Recommendations for treatment of symptomatic and ruptured TAAs

Early mortality after open repair of ruptured DTA is high as evidenced by a Swedish study from the pre-endovascular era that reported an in-hospital mortality approaching 100%.¹⁹⁹ The results with TEVAR have been much more promising. A multicenter trial of acute aortic catastrophes showed a mortality of 15% in the ruptured arm.²⁰⁰ This compared favorably with the results of open repair from the National Inpatient Sample database, which had an early mortality of 45%.²⁰¹ Indeed, a review of the Medicare database from 2004 to 2007 showed that the percentage of ruptured DTA patients who were treated with TEVAR increased from 17% in 2004 to 49% in 2007 (a total of 1033 patients treated),

with a significant decrease in mortality from 45% in open repair to 24% with TEVAR ($P < .001$).²⁰² It is likely that there is an early survival advantage to treating ruptured DTA with TEVAR over open repair.

There appear to be advantages to TEVAR over open repair of the DTA beyond survival. A meta-analysis comparing 224 patients from 28 articles showed a significantly lower incidence of perioperative myocardial infarction (11% vs 3.1%; $P < .05$) compared with open repair.²⁰³ In addition, a comparison of 161 patients from 7 hospitals during a 15-year period showed a lower incidence of the composite end point of stroke, paraplegia, and death in the TEVAR cohort compared with open repair (36.2% vs 21.7%; $P < .05$), but no difference was seen in the individual outcomes because of small numbers.²⁰⁴ Long-term outcomes have been reasonable after TEVAR for ruptured DTA. A review of 21 patients treated with TEVAR with a median follow-up of >5 years reported a late mortality of 52% with only one known aorta-related death.²⁰⁵

Most of the large series evaluating TEVAR for ruptured DTA are from administrative databases, such as Medicare and the National Inpatient Sample, and lack the anatomic granularity that would allow meaningful comparison of the cohort of patients undergoing each procedure (open TAA repair vs TEVAR). In addition, it is difficult to determine the state of the patient at the time of presentation as it is possible that one approach is favored in stable patients and another is used when a patient presents in extremis. Within these limitations, it appears that TEVAR for ruptured DTA is associated with improved survival and lower morbidity compared with open repair.⁵

Recommendation 35: We recommend TEVAR over open repair for the treatment of ruptured DTA when it is anatomically feasible. **Level of recommendation: Grade 1 (Strong), Quality of Evidence: B (Moderate)**

SURVEILLANCE AFTER TEVAR

Surveillance after TEVAR is critical to identify endoleaks after initial placement and to evaluate whether long-term complications appear, such as migration, aneurysm expansion despite no evidence of endoleak (type V endoleak, so-called endotension), new endoleaks, device failure (fracture, migration, component separation), stenosis, or occlusion. In addition, long-term evaluation may detect signs of graft infection. The most often reported protocol after TEVAR for aneurysm surveillance is clinical examination and CT scans at 1 month, 6 months, and yearly thereafter.^{206,207} When TEVAR is placed for emergent indications, earlier evaluation either during hospitalization or within 1 week of placement may be warranted.²⁰⁸

Difficulties in establishing surveillance protocols include variability in reporting of institutional protocols as well as reported rates of reintervention vs reporting

of new findings in the surveillance protocols. Low reintervention rates could imply the absence of significant findings on surveillance imaging or a lack of intervention despite the presence of new findings. Conversely, high reported reintervention rates could reflect either a high rate of significant findings or simply a more aggressive approach to the findings treated conservatively at other institutions. Recent evidence also shows that TEVAR surveillance may be best tailored to the indication for the TEVAR as certain pathologic processes may warrant more frequent surveillance. A publication by Meena et al²⁰⁹ evaluated 203 patients treated with TEVAR with follow-up CT scans and demonstrated aorta-related complications in 35% of patients, with sac expansion accounting for 77% of these.

Whereas long-term outcomes are beginning to be reported, patients undergoing TEVAR for DTA aneurysm with straightforward anatomy and who fit within the device's instructions for use criteria rarely require late reintervention. In a series of 82 patients treated for TAA, only 11% required reintervention at 60 months of follow-up.²⁰⁶ Indications for reintervention were type I endoleaks in about 7% and infection and type III endoleaks in 1% each. No secondary intervention was performed for aneurysm expansion or endograft collapse.²⁰⁶

In contrast, 63 consecutive patients treated in Essen, Germany, with TEVAR for PAU were followed up for a mean of 46 months. In this experience, 19% required reintervention for late endoleaks (6.3%), with the remainder requiring reintervention secondary to disease progression.²¹⁰ A review of the outcomes captured in the Hospital Episode Statistics database in England revealed that 6% of patients treated for intact aortic aneurysms required reintervention within 30 days after TEVAR.²¹¹ The average time to any reintervention was 28 months. In contrast to those treated for intact TAA, 33% of patients treated with TEVAR for ruptured aneurysms will require additional intervention at 3 years.²¹¹

Concern for long-term, cumulative radiation exposure has been growing, especially when TEVAR is performed in younger patients. Patients treated with TEVAR for intact aneurysms with favorable imaging findings by CTA at 1 month and 6 months are unlikely to have any complication in their lifetime that will need reintervention.²¹² Given the good outcomes exemplified in the two scenarios described before, it is not surprising that delayed follow-up imaging (>1.5 years) has been shown to be relatively safe in midterm studies.²¹³ However, there is an absence of long-term data supporting this approach. In addition, late stent graft collapse, infection, and endograft disruption can occur,²¹⁴ and late conversion to open repair occurs at an average of 5 years and up to 98 months after initial implantation, suggesting that patients undergoing TEVAR should be observed for life.^{101,215}

Recommendation 36: We recommend contrast-enhanced CT scanning at 1 month and 12 months after TEVAR and then yearly for life, with consideration of more frequent imaging if an endoleak or other abnormality of concern is detected at 1 month. **Level of recommendation: Grade 1 (Strong), Quality of Evidence: B (Moderate)**

Implementation remarks about surveillance.

1. In cases in which the 1-month CT scan demonstrates morphologic endograft concerns (eg, "bird beaking," infolding of endograft), endoleaks, or evidence of sac growth and in high-risk patients (eg, those treated for PAU or ruptured aortic aneurysms), repeated CTA with arterial and delayed phase imaging is recommended within 6 months.
2. In cases at low risk for expansion, such as those with a shrinking aneurysm sac and >3 years of stability, non-contrast-enhanced CT of the chest may be used to follow aneurysm sac size and component stability.
3. We can recommend neither eliminating TEVAR surveillance nor extending it further than annually, given the lack of long-term evidence of safety and because of evidence of aneurysm growth and new endoleaks reported, despite a previously sealed aneurysm.

SPECIAL TAA CONSIDERATIONS

Guidelines for hospital privileges have been established for TEVAR by the SVS.²¹⁶ Calligaro et al²¹⁷ suggested that the requirements for TEVAR include full basic privileges with either 10 TEVARs within the last 2 years or less than this minimum for surgeons with a robust EVAR experience, defined as 25 EVARs with 12 as the primary operator. Trainees should also be able to manage complex aortic patients as well as to perform adjunctive procedures, including iliac conduits and carotid-subclavian bypass grafting.

The relationship between volume and outcomes has been explored for TEVAR,²¹⁸⁻²²⁰ and the data supporting or refuting such a relationship are poor, mainly because these studies are typically underpowered and the data are heterogeneous, including EVAR and TEVAR, or TEVAR when used to treat multiple pathologic processes (ie, aneurysm and dissection). One study using the Medicare claims database from 1999 to 2007 documented a mortality rate for TEVAR in low-volume centers of 9% to 10%, whereas mortality was 7% in high-volume TEVAR centers. Despite these gross mortality differences, a multivariable model for mortality failed to show volume as a predictor ($P = .328$).²¹⁸ A second study using Medicare Provider and Analysis Review data also found no association between TEVAR volume and mortality.²¹⁹ Finally, a study using a Medicare Provider and Analysis Review data set in 10,000 patients undergoing TEVAR found no clear relationship between hospital volume

effect and survival. However, these same practitioners suggested that using a mixed effects Cox model demonstrated an "independent hospital effect" associated with certain hospitals, with a death 50% of what occurred at other hospitals.²²⁰ These data suggest that at present, no clear conclusion can be drawn between hospital volume and outcomes after TEVAR. Importantly, even fewer data are available to examine the role of individual clinician TEVAR volume and outcomes.

CONCLUSIONS

TEVAR is used to treat a myriad of aortic diseases. Whereas there are no randomized, controlled trials comparing open and endovascular DTA repair directly and probably never will be, consensus documents, large administrative data sets, and meta-analyses have strongly suggested that TEVAR for isolated descending TAAs should be the primary method of repair in both the elective and emergent setting based on improved short-term and midterm mortality as well as morbidity.

REFERENCES

- Gloviczki P, Comerota AJ, Dalsing MC, Eklof BG, Gillespie DL, Gloviczki ML, et al. The care of patients with varicose veins and associated chronic venous diseases: clinical practice guidelines of the Society for Vascular Surgery and the American Venous Forum. *J Vasc Surg* 2011;53(Suppl):2S-48S.
- Fleisher LA, Fleischmann KE, Auerbach AD, Barnason SA, Beckman JA, Bozkurt B, et al. 2014 ACC/AHA guideline on perioperative cardiovascular evaluation and management of patients undergoing noncardiac surgery: a report of the American College of Cardiology/American Heart Association Task Force on practice guidelines. *J Am Coll Cardiol* 2014;64:e77-137.
- Fillinger MD, Greenberg RK, McKinsey JF, Chaikof EL; Society for Vascular Surgery Ad Hoc Committee on TEVAR Reporting Guidelines. Reporting standards for thoracic endovascular aortic repair (TEVAR). *J Vasc Surg* 2010;52:1022-33.
- Guyatt GH, Alonso-Coello P, Schünemann HJ, Djulbegovic B, Nothacker M, Lange S, et al. Guideline panels should seldom make good practice statements: guidance from the GRADE Working Group. *J Clin Epidemiol* 2016;80:3-7.
- Alsawas M, Zaiem F, Larrea-Mantilla L, Almasri J, Erwin PJ, Upchurch GR Jr, et al. Effectiveness of surgical interventions for thoracic aortic aneurysms: a systematic review and meta-analysis. *J Vasc Surg* 2017;66:1258-68.
- Hiratzka LF, Bakris GL, Beckman JA, Bersin RM, Carr VF, Casey DE Jr, et al. 2010 ACCF/AHA/AATS/ACR/ASA/SCA/SCAI/SIR/STS/SVM guidelines for the diagnosis and management of patients with Thoracic Aortic Disease: a report of the American College of Cardiology Foundation/American Heart Association Task Force on Practice Guidelines, American Association for Thoracic Surgery, American College of Radiology, American Stroke Association, Society of Cardiovascular Anesthesiologists, Society for Cardiovascular Angiography and Interventions, Society of Interventional Radiology, Society of Thoracic Surgeons, and Society for Vascular Medicine. *Circulation* 2010;121:e266-369.
- Lee WA, Matsumura JS, Mitchell RS, Farber MA, Greenberg RK, Azizzadeh A, et al. Endovascular repair of traumatic thoracic aortic injury: clinical practice guidelines of the Society for Vascular Surgery. *J Vasc Surg* 2011;53:187-92.
- Oladokun D, Patterson B, Sobocinski J, Karthikesalingam A, Loftus I, Thompson M, et al. Systematic review of the growth rates and influencing factors in thoracic aortic aneurysms. *Eur J Vasc Endovasc Surg* 2016;51:674-81.
- Centers for Disease Control and Prevention. CDC WONDER. Underlying cause of death 1999-2016. Available at: <https://wonder.cdc.gov/controller/datarequest/D76j;sessionid=0B2C1F1224200E7218A57C9E4FF682AF>. Accessed February 11, 2018.
- Bickerstaff LK, Pairolero PC, Hollier LH, Melton LJ, Van Peenen HJ, Cherry KJ, et al. Thoracic aortic aneurysms: a population-based study. *Surgery* 1982;92:1103-8.
- Olsson C, Thelin S, Ståhle E, Ekblom A, Granath F. Thoracic aortic aneurysm and dissection: increasing prevalence and improved outcomes reported in a nationwide population-based study of more than 14 000 cases from 1987 to 2002. *Circulation* 2006;114:2611-8.
- LaRoy LL, Cormier P, Matalon T, Patel S, Turner D, Silver B. Imaging of abdominal aortic aneurysms. *AJR Am J Roentgenol* 1989;152:785-92.
- Pleumeekers H, Hoes A, Van Der Does E, Van Urk H, Hofman A, De Jong P, et al. Aneurysms of the abdominal aorta in older adults. The Rotterdam study. *Am J Epidemiol* 1995;142:1291-9.
- Biddinger A, Rocklin M, Coselli J, Milewicz DM. Familial thoracic aortic dilatations and dissections: a case control study. *J Vasc Surg* 1997;25:506-11.
- Coady MA, Davies RR, Roberts M, Goldstein LJ, Rogalski MJ, Rizzo JA, et al. Familial patterns of thoracic aortic aneurysms. *Arch Surg* 1999;134:361-7.
- Hasham SN, Willing MC, Guo DC, Muilenburg A, He R, Tran VT, et al. Mapping a locus for familial thoracic aortic aneurysms and dissections (TAAD2) to 3p24-25. *Circulation* 2003;107:3184-90.
- Guo DC, Papke CL, He R, Milewicz DM. Pathogenesis of thoracic and abdominal aortic aneurysms. *Ann N Y Acad Sci* 2006;1085:339-52.
- Coady MA, Rizzo JA, Goldstein LJ, Elefteriades JA. Natural history, pathogenesis, and etiology of thoracic aortic aneurysms and dissections. *Cardiol Clin* 1999;17:615-35.
- Moreno-Cabral C, Miller D, Mitchell R, Stinson E, Oyer P, Jamieson S, et al. Degenerative and atherosclerotic aneurysms of the thoracic aorta. Determinants of early and late surgical outcome. *J Thorac Cardiovasc Surg* 1984;88:1020-32.
- Juvonen T, Ergin MA, Galla JD, Lansman SL, McCullough JN, Nguyen K, et al. Risk factors for rupture of chronic type B dissections. *J Thorac Cardiovasc Surg* 1999;117:776-86.
- Dapunt OE, Galla JD, Sadeghi AM, Lansman SL, Mezrow CK, de Asla RA, et al. The natural history of thoracic aortic aneurysms. *J Thorac Cardiovasc Surg* 1994;107:1323-32.
- Elefteriades JA. Natural history of thoracic aortic aneurysms: indications for surgery, and surgical versus nonsurgical risks. *Ann Thorac Surg* 2002;74:S1877-80; discussion: S1892-8.
- McNamara JJ, Pressler VM. Natural history of arteriosclerotic thoracic aortic aneurysms. *Ann Thorac Surg* 1978;26:468-73.
- Pressler V, McNamara J. Aneurysm of the thoracic aorta. Review of 260 cases. *J Thorac Cardiovasc Surg* 1985;89:50-4.
- Davies RR, Goldstein LJ, Coady MA, Tittle SL, Rizzo JA, Kopf GS, et al. Yearly rupture or dissection rates for thoracic aortic aneurysms: simple prediction based on size. *Ann Thorac Surg* 2002;73:17-28.
- Crawford ES, DeNatale RW. Thoracoabdominal aortic aneurysm: observations regarding the natural course of the disease. *J Vasc Surg* 1986;3:578-82.

27. Cronenwett J, Murphy T, Zelenock G, Whitehouse W Jr, Lindenauer S, Graham LM, et al. Actuarial analysis of variables associated with rupture of small abdominal aortic aneurysms. *Surgery* 1985;98:472-83.
28. Cambria RA, Gloviczki P, Stanson AW, Cherry KJ, Bower TC, Hallett JW, et al. Outcome and expansion rate of 57 thoracoabdominal aortic aneurysms managed nonoperatively. *Am J Surg* 1995;170:213-7.
29. Griep RB, Ergin MA, Galla JD, Lansman SL, McCullough JN, Nguyen KH, et al. Natural history of descending thoracic and thoracoabdominal aneurysms. *Ann Thorac Surg* 1999;67:1927-30.
30. Upchurch GR Jr, Perry RJ. Thoracic and thoracoabdominal aortic aneurysms: etiology, epidemiology, natural history, medical management, and decision making. In: Sidawy AN, Perler BA, editors. *Rutherford's vascular surgery and endovascular therapy*. 9th ed. Philadelphia: Elsevier; 2019. p. 970-86.
31. Colman MW, Hornicek FJ, Schwab JH. Spinal cord blood supply and its surgical implications. *J Am Acad Orthop Surg* 2015;23:581-91.
32. Nijenhuis RJ, Leiner T, Cornips EM, Wilmsink JT, Jacobs MJ, van Engelsehoven JM, et al. Spinal cord feeding arteries at MR angiography for thoracoscopic spinal surgery: feasibility study and implications for surgical approach. *Radiology* 2004;233:541-7.
33. Madhwal S, Rajagopal V, Bhatt DL, Bajzer CT, Whitlow P, Kapadia SR. Predictors of difficult carotid stenting as determined by aortic arch angiography. *J Invasive Cardiol* 2008;20:200-4.
34. Evangelista A, Maldonado G, Moral S, Teixido-Tura G, Lopez A, Cuellar H, et al. Intramural hematoma and penetrating ulcer in the descending aorta: differences and similarities. *Ann Cardiothorac Surg* 2019;8:456-70.
35. Gravanis MB. Giant cell arteritis and Takayasu aortitis: morphologic, pathogenetic and etiologic factors. *Int J Cardiol* 2000;75(Suppl 1):S21-33; discussion: S35-6.
36. Koster MJ, Matteson EL, Warrington KJ. Recent advances in the clinical management of giant cell arteritis and Takayasu arteritis. *Curr Opin Rheumatol* 2016;28:211-7.
37. Moral S, Cuellar H, Avegliano G, Ballesteros E, Salcedo MT, Ferreira-González I, et al. Clinical implications of focal intimal disruption in patients with type B intramural hematoma. *J Am Coll Cardiol* 2017;69:28-39.
38. Chou AS, Ziganshin BA, Charilaou P, Tranquilli M, Rizzo JA, Elefteriades JA. Long-term behavior of aortic intramural hematomas and penetrating ulcers. *J Thorac Cardiovasc Surg* 2016;151:361-72.
39. Eggebrecht H, Plicht B, Kahlert P, Erbel R. Intramural hematoma and penetrating ulcers: indications to endovascular treatment. *Eur J Vasc Endovasc Surg* 2009;38:659-65.
40. Macedo TA, Stanson AW, Oderich GS, Johnson CM, Panneton JM, Tie ML. Infected aortic aneurysms: imaging findings. *Radiology* 2004;231:250-7.
41. Riesenman PJ, Brooks JD, Farber MA. Thoracic endovascular aortic repair of aortobronchial fistulas. *J Vasc Surg* 2009;50:992-8.
42. Hoffman JL, Gray RG, Minich LL, Wilkinson SE, Heywood M, Edwards R, et al. Screening for aortic aneurysm after treatment of coarctation. *Pediatr Cardiol* 2014;35:47-52.
43. Lala S, Scali ST, Feezor RJ, Chandrekashar S, Giles KA, Fatima J, et al. Outcomes of thoracic endovascular aortic repair in adult coarctation patients. *J Vasc Surg* 2018;67:369-81.
44. van Son JA, Konstantinov IE, Burckhard F, Kommerell and Kommerell's diverticulum. *Tex Heart Inst J* 2002;29:109-12.
45. Akiko T, Milner R, Takeyoshi O. Kommerell's diverticulum in the current era: a comprehensive review. *Gen Thorac Cardiovasc Surg* 2015;63:245-69.
46. Austin EH, Wolfe WG. Aneurysm of aberrant subclavian artery with a review of the literature. *J Vasc Surg* 1985;2:571-7.
47. Cinà CS, Althani H, Pasenau J, Abouzahr L. Kommerell's diverticulum and right-sided aortic arch: a cohort study and review of the literature. *J Vasc Surg* 2004;39:131-9.
48. Ota T, Okada K, Takanashi S, Yamamoto S, Okita Y. Surgical treatment for Kommerell's diverticulum. *J Thorac Cardiovasc Surg* 2006;131:574-8.
49. Restrepo CS, Betancourt SL, Martinez-Jimenez S, Gutierrez FR. Aortic tumors. *Semin Ultrasound CT MR* 2012;33:265-72.
50. Baril DT, Carroccio A, Palchik E, Ellozy SH, Jacobs TS, Teodorescu V, et al. Endovascular treatment of complicated aortic aneurysms in patients with underlying arteriopathies. *Ann Vasc Surg* 2006;20:464-71.
51. Canaud L, Ozdemir BA, Bee WW, Bahia S, Holt P, Thompson M. Thoracic endovascular aortic repair in management of aortoesophageal fistulas. *J Vasc Surg* 2014;59:248-54.
52. Onohara T, Nakamura Y, Kishimoto Y, Harada S, Fujiwara Y, Saiki M, et al. Two cases of thoracic aortic aneurysm with right aortic arch: comparison of two operative strategies for hybrid thoracic endovascular repair. *Ann Vasc Dis* 2014;7:343-6.
53. Yamasaki M, Hashimoto J, Yoshino K, Abe K, Misumi H. Giant abdominal sarcoma that caused aortic rupture at the twelfth thoracic level. *J Cardiol Cases* 2018;17:130-2.
54. Ho ML, Gutierrez FR. Chest radiography in thoracic polytrauma. *AJR Am J Roentgenol* 2009;192:599-612.
55. Ropp A, Waite S, Reede D, Patel J. Did I miss that: subtle and commonly missed findings on chest radiographs. *Curr Probl Diagn Radiol* 2015;44:277-89.
56. Jagannath AS, Sos TA, Lockhart SH, Saddekni S, Sniderman KW. Aortic dissection: a statistical analysis of the usefulness of plain chest radiographic findings. *AJR Am J Roentgenol* 1986;147:1123-6.
57. Whitten CR, Khan S, Munneke GJ, Grubnic S. A diagnostic approach to mediastinal abnormalities. *Radiographics* 2007;27:657-71.
58. Cullen EL, Lantz EJ, Johnson CM, Young PM. Traumatic aortic injury: CT findings, mimics, and therapeutic options. *Cardiovasc Diagn Ther* 2014;4:238-44.
59. Fiorucci B, Banafsche R, Jerkku T, Pichlmaier M, Kölbel T, Rantner B, et al. Thoracic aortic aneurysms—diagnosis and treatment strategies. *Dtsch Med Wochenschr* 2019;144:146-51.
60. Hansen NJ. Computed tomographic angiography of the abdominal aorta. *Radiol Clin North Am* 2016;54:35-54.
61. Wang GJ, Fairman RM. Endovascular repair of the thoracic aorta. *Semin Intervent Radiol* 2009;26:17-24.
62. Budovec JJ, Pollema M, Grogan M. Update on multi-detector computed tomography angiography of the abdominal aorta. *Radiol Clin North Am* 2010;48:283-309.
63. Fleischmann D. CT angiography: injection and acquisition technique. *Radiol Clin North Am* 2010;48:237-47.
64. Ahmed S, Zimmerman SL, Johnson PT, Lai H, Kawamoto S, Horton KM, et al. MDCT interpretation of the ascending aorta with semiautomated measurement software: improved reproducibility compared with manual techniques. *J Cardiovasc Comput Tomogr* 2014;8:108-14.
65. Entezari P, Kino A, Honarmand AR, Galizia MS, Yang Y, Collins J, et al. Analysis of the thoracic aorta using a semi-automated post processing tool. *Eur J Radiol* 2013;82:1558-64.
66. Strobl FF, Sommer WH, Haack M, Nikolaou K, Meimarakis G, Koepfel TA, et al. [Computed tomography angiography as

- the basis for optimized therapy planning before endovascular aneurysm repair (EVAR)]. *Radiologe* 2013;53:495-502.
67. Stojanovska J, Rodriguez K, Mueller GC, Agarwal PP. MR imaging of the thoracic aorta. *Magn Reson Imaging Clin N Am* 2015;23:273-91.
68. Holloway BJ, Rosewarne D, Jones RG. Imaging of thoracic aortic disease. *Br J Radiol* 2011;84(Spec No 3):S338-54.
69. Miyazaki M, Akahane M. Non-contrast enhanced MR angiography: established techniques. *J Magn Reson Imaging* 2012;35:1-19.
70. Janosi RA, Gorla R, Rogmann K, Kahlert P, Tsagakakis K, Dohle DS, et al. Validation of intravascular ultrasound for measurement of aortic diameters: comparison with multi-detector computed tomography. *Minim Invasive Ther Allied Technol* 2015;24:289-95.
71. Han SM, Elsayed RS, Ham SW, Mahajan A, Fleischman F, Rowe VL, et al. Comparison of intravascular ultrasound- and centerline computed tomography-determined aortic diameters during thoracic endovascular aortic repair. *J Vasc Surg* 2017;66:1184-91.
72. Lewington S, Clarke R, Qizilbash N, Peto R, Collins R; Prospective Studies Collaboration. Age-specific relevance of usual blood pressure to vascular mortality: a meta-analysis of individual data for one million adults in 61 prospective studies. *Lancet* 2002;360:1903-13.
73. Neal B, MacMahon S, Chapman N; Blood Pressure Lowering Treatment Trialists' Collaboration. Effects of ACE inhibitors, calcium antagonists, and other blood-pressure-lowering drugs: results of prospectively designed overviews of randomised trials. *Blood Pressure Lowering Treatment Trialists' Collaboration. Lancet* 2000;356:1955-64.
74. Evans J, Powell JT, Schwalbe E, Loftus IM, Thompson MM. Simvastatin attenuates the activity of matrix metalloproteinase-9 in aneurysmal aortic tissue. *Eur J Vasc Endovasc Surg* 2007;34:302-3.
75. Ockene IS, Miller NH. Cigarette smoking, cardiovascular disease, and stroke: a statement for healthcare professionals from the American Heart Association. American Heart Association Task Force on Risk Reduction. *Circulation* 1997;96:3243-7.
76. Kihara T, Yamagishi K, Iso H, Tamakoshi A; JACC Study Group. Passive smoking and mortality from aortic dissection or aneurysm. *Atherosclerosis* 2017;263:145-50.
77. Coselli JS, LeMaire SA, Miller CC 3rd, Schmittling ZC, Koksoy C, Pagan J, et al. Mortality and paraplegia after thoracoabdominal aortic aneurysm repair: a risk factor analysis. *Ann Thorac Surg* 2000;69:409-14.
78. Barbato JE, Kim JY, Zenati M, Abu-Hamad G, Rhee RY, Makaroun MS, et al. Contemporary results of open repair of ruptured descending thoracic and thoracoabdominal aortic aneurysms. *J Vasc Surg* 2007;45:667-76.
79. Cowan JA, Dimick JB, Henke PK, Huber TS, Stanley JC, Upchurch GR. Surgical treatment of intact thoracoabdominal aortic aneurysms in the United States: hospital and surgeon volume-related outcomes. *J Vasc Surg* 2003;37:1169-74.
80. Makaroun MS, Dillavou ED, Kee ST, Sicard G, Chaikof E, Bavaria J, et al. Endovascular treatment of thoracic aortic aneurysms: results of the phase II multicenter trial of the GORE TAG thoracic endoprosthesis. *J Vasc Surg* 2005;41:1-9.
81. Heijmen RH, Deblier IC, Moll FL, Dossche KM, van den Berg JC, Overtom TT, et al. Endovascular stent-grafting for descending thoracic aortic aneurysms. *Eur J Cardiothorac Surg* 2002;21:5-9.
82. Chiu P, Goldstone AB, Schaffer JM, Lingala B, Miller DC, Mitchell RS, et al. Endovascular versus open repair of intact descending thoracic aortic aneurysms. *J Am Coll Cardiol* 2019;73:643-51.
83. Patel HJ, Sood V, Williams DM, Dasika NL, Diener AC, Deeb GM. Late outcomes with repair of penetrating thoracic aortic ulcers: the merits of an endovascular approach. *Ann Thorac Surg* 2012;94:516-22; discussion: 522-3.
84. Day C, Buckenham T. Endovascular repair of the thoracic aorta: predictors of 30-day mortality in patients on the New Zealand Thoracic Aortic Stent Database (NZ TAS). *Eur J Vasc Endovasc Surg* 2009;37:160-5.
85. Patterson BO, Vidal-Diez A, Holt PJ, Scali ST, Beck AW, Thompson MM. Predicting mid-term all-cause mortality in patients undergoing elective endovascular repair of a descending thoracic aortic aneurysm. *Ann Surg* 2016;264:1162-7.
86. Abbara I, Romagnoli C, Montedori A, Cirotchi R. Thoracic stent graft versus surgery for thoracic aneurysm. *Cochrane Database Syst Rev* 2016;6:CD006796.
87. Abbara I, Romagnoli C, Montedori A, Cirotchi R. Thoracic stent graft versus surgery for thoracic aneurysm. *Cochrane Database Syst Rev* 2009;1:CD006796.
88. Bavaria JE, Appoo JJ, Makaroun MS, Verter J, Yu ZF, Mitchell RS, et al. Endovascular stent grafting versus open surgical repair of descending thoracic aortic aneurysms in low-risk patients: a multicenter comparative trial. *J Thorac Cardiovasc Surg* 2007;133:369-77.
89. Matsumura JS, Cambria RP, Dake MD, Moore RD, Svensson LG, Snyder S, et al. International controlled clinical trial of thoracic endovascular aneurysm repair with the Zenith TX2 endovascular graft: 1-year results. *J Vasc Surg* 2008;47:247-57.e3.
90. Fairman RM, Criado F, Farber M, Kwolek C, Mehta M, White R, et al. Pivotal results of the Medtronic Vascular Talent Thoracic Stent Graft System: the VALOR trial. *J Vasc Surg* 2008;48:546-54.
91. Gore. Available at: <http://www.goremedical.com>. Accessed March 24, 2016.
92. Valiant. Available at: <http://www.medtronic.com/for-health-care-professionals/products-therapies/cardiovascular/aortic-stent-grafts/ValiantThoracicStentGraft/indications-safety-warnings.html>. Accessed March 24, 2016.
93. Cook. Zenith AlphaThoracic Endovascular Graft (P140016) annual clinical update (2016). Available at: <https://www.cookmedical.com/products>. Accessed February 26, 2018.
94. Bolton. Available at: <https://terumo-aortic.com/products/relay/>. Accessed March 24, 2016.
95. Food and Drug Administration. Cook Medical Inc. recalls Zenith AlphaThoracic Endovascular Graft for the treatment of blunt traumatic aortic injury (BTAI) due to the potential formation of thrombus inside the device after implantation. Available at: <https://www.fda.gov/MedicalDevices/Safety/ListofRecalls/ucm571853.htm>. Accessed February 26, 2018.
96. Escobar GA, Upchurch GR Jr. Management of thoracoabdominal aortic aneurysms. *Curr Probl Surg* 2011;48:70-133.
97. Evangelista A, Czerny M, Nienaber C, Schepens M, Rousseau H, Cao P, et al. Interdisciplinary expert consensus on management of type B intramural haematoma and penetrating aortic ulcer. *Eur J Cardiothorac Surg* 2015;47:209-17.
98. Gifford SM, Duncan AA, Greiten LE, Gloviczki P, Oderich GS, Kalra M, et al. The natural history and outcomes for thoracic and abdominal penetrating aortic ulcers. *J Vasc Surg* 2016;63:1182-8.
99. Ganaha F, Miller DC, Sugimoto K, Do YS, Minamiguchi H, Saito H, et al. Prognosis of aortic intramural hematoma with and without penetrating atherosclerotic ulcer: a clinical and radiological analysis. *Circulation* 2002;106:342-8.

100. Adkisson CD, Oldenburg WA, Belli EV, Harris AS, Walser EM, Hakaim AG. Treatment of a mycotic descending thoracic aortic aneurysm using endovascular stent-graft placement and rifampin infusion with postoperative aspiration of the aneurysm sac. *Vasc Endovascular Surg* 2011;45:765-8.
101. Davis FM, Miller DJ, Newton D, Arya S, Escobar GA. Successful treatment of a mycotic multifocal thoracoabdominal aortic aneurysm as a late sequelae of intravesical bacillus Calmette-Guerin therapy: case report and literature review. *Ann Vasc Surg* 2015;29:840.e9-13.
102. Mezzetto L, Treppiedi E, Scorsone L, Giacomuzzi S, Perandini S, Macri M, et al. Thoracic aortic pseudoaneurysm after esophageal perforation and mediastinitis caused by accidental ingestion of a mutton bone: a case report on staged endoscopic and endovascular treatments. *Ann Vasc Surg* 2016;30:307.e15-9.
103. Setacci C, de Donato G, Setacci F. Endografts for the treatment of aortic infection. *Semin Vasc Surg* 2011;24:242-9.
104. Escobar GA, Eliason JL, Hurie J, Arya S, Rectenwald JE, Coleman DM. Rifampin soaking Dacron-based endografts for implantation in infected aortic aneurysms—new application of a time-tested principle. *Ann Vasc Surg* 2014;28:744-8.
105. Heneghan RE, Singh N, Starnes BW. Successful emergent endovascular repair of a ruptured mycotic thoracic aortic aneurysm. *Ann Vasc Surg* 2015;29:843.e1-6.
106. van Dorp M, Gilbers M, Lauwers P, Van Schil PE, Hendriks JM. Local anesthesia for percutaneous thoracic endovascular aortic repair. *Aorta (Stamford)* 2016;4:78-82.
107. Hogendoorn W, Schlosser FJ, Muhs BE, Popescu WM. Surgical and anesthetic considerations for the endovascular treatment of ruptured descending thoracic aortic aneurysms. *Curr Opin Anaesthesiol* 2014;27:12-20.
108. DeSart K, Scali ST, Feezor RJ, Hong M, Hess PJ Jr, Beaver TM, et al. Fate of patients with spinal cord ischemia complicating thoracic endovascular aortic repair. *J Vasc Surg* 2013;58:635-42.e2.
109. Buth J, Harris PL, Hobo R, van Eps R, Cuypers P, Duijm L, et al. Neurologic complications associated with endovascular repair of thoracic aortic pathology: incidence and risk factors. A study from the European Collaborators on Stent/Graft Techniques for Aortic Aneurysm Repair (EUROSTAR) registry. *J Vasc Surg* 2007;46:1103-10.
110. Eagleton MJ, Shah S, Petkosevek D, Mastracci TM, Greenberg RK. Hypogastric and subclavian artery patency affects onset and recovery of spinal cord ischemia associated with aortic endografting. *J Vasc Surg* 2014;59:89-94.
111. O'Callaghan A, Mastracci TM, Eagleton MJ. Staged endovascular repair of thoracoabdominal aortic aneurysms limits incidence and severity of spinal cord ischemia. *J Vasc Surg* 2015;61:347-54.
112. Acher CW, Wynn MM, Hoch JR, Popic P, Archibald J, Turnipseed WD. Combined use of cerebral spinal fluid drainage and naloxone reduces the risk of paraplegia in thoracoabdominal aneurysm repair. *J Vasc Surg* 1994;19:236-46.
113. Acher C, Acher CW, Marks E, Wynn M. Intraoperative neuroprotective interventions prevent spinal cord ischemia and injury in thoracic endovascular aortic repair. *J Vasc Surg* 2016;63:1458-65.
114. Melissano G, Kahlberg A, Bertoglio L, Chiesa R. Endovascular exclusion of thoracic aortic aneurysms with the 1- and 2-component Zenith TX2 TAA endovascular grafts: analysis of 2-year data from the TX2 pivotal trial. *J Endovasc Ther* 2011;18:338-49.
115. Bobadilla JL, Wynn M, Tefera G, Acher CW. Low incidence of paraplegia after thoracic endovascular aneurysm repair with proactive spinal cord protective protocols. *J Vasc Surg* 2013;57:1537-42.
116. Keyhani K, Miller CC 3rd, Estrera AL, Wegryn T, Sheinbaum R, Safi HJ. Analysis of motor and somatosensory evoked potentials during thoracic and thoracoabdominal aortic aneurysm repair. *J Vasc Surg* 2009;49:36-41.
117. Banga PV, Oderich GS, Reis de Souza L, Hofer J, Cazares Gonzalez ML, Pulido JN, et al. Neuromonitoring, cerebrospinal fluid drainage, and selective use of iliofemoral conduits to minimize risk of spinal cord injury during complex endovascular aortic repair. *J Endovasc Ther* 2016;23:139-49.
118. Arnaoutakis DJ, Arnaoutakis GJ, Beaulieu RJ, Abularrage CJ, Lum YW, Black JH 3rd. Results of adjunctive spinal drainage and/or left subclavian artery bypass in thoracic endovascular aortic repair. *Ann Vasc Surg* 2014;28:65-73.
119. Keith CJ Jr, Passman MA, Carignan MJ, Parmar GM, Nagre SB, Patterson MA, et al. Protocol implementation of selective postoperative lumbar spinal drainage after thoracic aortic endograft. *J Vasc Surg* 2012;55:1-8.
120. Bisdas T, Panuccio G, Sugimoto M, Torsello G, Austermann M. Risk factors for spinal cord ischemia after endovascular repair of thoracoabdominal aortic aneurysms. *J Vasc Surg* 2015;61:1408-16.
121. Ullery BW, Cheung AT, Fairman RM, Jackson BM, Woo EY, Bavaria J, et al. Risk factors, outcomes, and clinical manifestations of spinal cord ischemia following thoracic endovascular aortic repair. *J Vasc Surg* 2011;54:677-84.
122. Wong CS, Healy D, Canning C, Coffey JC, Boyle JR, Walsh SR. A systematic review of spinal cord injury and cerebrospinal fluid drainage after thoracic aortic endografting. *J Vasc Surg* 2012;56:1438-47.
123. Khan NR, Smalley Z, Nesvick CL, Lee SL, Michael LM 2nd. The use of lumbar drains in preventing spinal cord injury following thoracoabdominal aortic aneurysm repair: an updated systematic review and meta-analysis. *J Neurosurg Spine* 2016;25:383-93.
124. Scali ST, Kim M, Kubilis P, Feezor RJ, Giles KA, Miller B, et al. Implementation of a bundled protocol significantly reduces risk of spinal cord ischemia after branched or fenestrated endovascular aortic repair. *J Vasc Surg* 2018;67:409-23.
125. Estrera AL, Sheinbaum R, Miller CC, Azizzadeh A, Walkes JC, Lee TY, et al. Cerebrospinal fluid drainage during thoracic aortic repair: safety and current management. *Ann Thorac Surg* 2009;88:9-15.
126. Feezor RJ, Lee WA. Management of the left subclavian artery during TEVAR. *Semin Vasc Surg* 2009;22:159-64.
127. Matsumura JS, Lee WA, Mitchell RS, Farber MA, Murad MH, Lumsden AB, et al. The Society for Vascular Surgery Practice Guidelines: management of the left subclavian artery with thoracic endovascular aortic repair. *J Vasc Surg* 2009;50:1155-8.
128. Zamor KC, Eskandari MK, Rodriguez HE, Ho KJ, Morasch MD, Hoel AW. Outcomes of thoracic endovascular aortic repair and subclavian revascularization techniques. *J Am Coll Surg* 2015;221:93-100.
129. Geisbusch S, Stefanovic A, Koruth JS, Lin HM, Morgello S, Weisz DJ, et al. Endovascular coil embolization of segmental arteries prevents paraplegia after subsequent thoracoabdominal aneurysm repair: an experimental model. *J Thorac Cardiovasc Surg* 2014;147:220-6.
130. Etz CD, Debus ES, Mohr FW, Kolbel T. First-in-man endovascular preconditioning of the paraspinal collateral network by segmental artery coil embolization to prevent ischemic spinal cord injury. *J Thorac Cardiovasc Surg* 2015;149:1074-9.

131. Cheng D, Martin J, Shennib H, Dunning J, Muneretto C, Schueler S, et al. Endovascular aortic repair versus open surgical repair for descending thoracic aortic disease: a systematic review and meta-analysis of comparative studies. *J Am Coll Cardiol* 2010;55:986-1001.
132. Gutsche JT, Cheung AT, McGarvey ML, Moser WG, Szeto W, Carpenter JP, et al. Risk factors for perioperative stroke after thoracic endovascular aortic repair. *Ann Thorac Surg* 2007;84:1195-200.
133. Tsilimparis N, Debus S, Chen M, Zhou Q, Seale MM, Kolbel T. Results from the Study to Assess Outcomes After Endovascular Repair for Multiple Thoracic Aortic Diseases (SUMMIT). *J Vasc Surg* 2018;68:1324-34.
134. Contrella BN, Sabri SS, Tracci MC, Stone JR, Kern JA, Upchurch GR, et al. Outcomes of coverage of the left subclavian artery during endovascular repair of the thoracic aorta. *J Vasc Interv Radiol* 2015;26:1609-14.
135. Waterford SD, Chou D, Bombien R, Uzun I, Shah A, Khoynzhad A. Left subclavian arterial coverage and stroke during thoracic aortic endografting: a systematic review. *Ann Thorac Surg* 2016;101:381-9.
136. Patterson BO, Holt PJ, Nienaber C, Fairman RM, Heijmen RH, Thompson MM. Management of the left subclavian artery and neurologic complications after thoracic endovascular aortic repair. *J Vasc Surg* 2014;60:1491-7.
137. Bradshaw RJ, Ahanchi SS, Powell O, Larion S, Brandt C, Soult MC, et al. Left subclavian artery revascularization in zone 2 thoracic endovascular aortic repair is associated with lower stroke risk across all aortic diseases. *J Vasc Surg* 2017;65:1270-9.
138. Maldonado TS, Dexter D, Rockman CB, Veith FJ, Garg K, Arko F, et al. Left subclavian artery coverage during thoracic endovascular aortic aneurysm repair does not mandate revascularization. *J Vasc Surg* 2013;57:116-24.
139. Thierfelder KM, Baumann AB, Sommer WH, Armbruster M, Opherck C, Janssen H, et al. Vertebral artery hypoplasia: frequency and effect on cerebellar blood flow characteristics. *Stroke* 2014;45:1363-8.
140. Reece TB, Gazoni LM, Cherry KJ, Peeler BB, Dake M, Matsumoto AH, et al. Reevaluating the need for left subclavian artery revascularization with thoracic endovascular aortic repair. *Ann Thorac Surg* 2007;84:1201-5; discussion: 1205.
141. Woo EY, Carpenter JP, Jackson BM, Pochettino A, Bavaria JE, Szeto WY, et al. Left subclavian artery coverage during thoracic endovascular aortic repair: a single-center experience. *J Vasc Surg* 2008;48:555-60.
142. Rizvi AZ, Murad MH, Fairman RM, Erwin PJ, Montori VM. The effect of left subclavian artery coverage on morbidity and mortality in patients undergoing endovascular thoracic aortic interventions: a systematic review and meta-analysis. *J Vasc Surg* 2009;50:1159-69.
143. Holt PJ, Johnson C, Hinchliffe RJ, Morgan R, Jahingiri M, Loftus IM, et al. Outcomes of the endovascular management of aortic arch aneurysm: implications for management of the left subclavian artery. *J Vasc Surg* 2010;51:1329-38.
144. von Allmen RS, Gahl B, Powell JT. Editor's choice—incidence of stroke following thoracic endovascular aortic repair for descending aortic aneurysm: a systematic review of the literature with meta-analysis. *Eur J Vasc Endovasc Surg* 2017;53:176-84.
145. Chung J, Kasirajan K, Veeraswamy RK, Dodson TF, Salam AA, Chaikof EL, et al. Left subclavian artery coverage during thoracic endovascular aortic repair and risk of perioperative stroke or death. *J Vasc Surg* 2011;54:979-84.
146. Scali ST, Chang CK, Pape SC, Feezor RJ, Berceli SA, Huber TS, et al. Subclavian revascularization in the age of thoracic endovascular aortic repair and comparison of outcomes in patients with occlusive disease. *J Vasc Surg* 2013;58:901-9.
147. Duran M, Grotemeyer D, Danch MA, Grabitz K, Schelzig H, Sagban TA. Subclavian carotid transposition: immediate and long-term outcomes of 126 surgical reconstructions. *Ann Vasc Surg* 2015;29:397-403.
148. Lee TC, Andersen ND, Williams JB, Bhattacharya SD, McCann RL, Hughes GC. Results with a selective revascularization strategy for left subclavian artery coverage during thoracic endovascular aortic repair. *Ann Thorac Surg* 2011;92:97-102.
149. van der Weijde E, Saouti N, Vos JA, Tromp SC, Heijmen RH. Surgical left subclavian artery revascularization for thoracic aortic stent grafting: a single-centre experience in 101 patients. *Interact Cardiovasc Thorac Surg* 2018;27:284-9.
150. Cina CS, Safar HA, Lagana A, Arena G, Clase CM. Subclavian carotid transposition and bypass grafting: consecutive cohort study and systematic review. *J Vasc Surg* 2002;35:422-9.
151. Ahanchi SS, Almaroof B, Stout CL, Panneton JM. In situ laser fenestration for revascularization of the left subclavian artery during emergent thoracic endovascular aortic repair. *J Endovasc Ther* 2012;19:226-30.
152. McWilliams RG, Murphy M, Hartley D, Lawrence-Brown MM, Harris PL. In situ stent-graft fenestration to preserve the left subclavian artery. *J Endovasc Ther* 2004;11:170-4.
153. Liu G, Qin J, Cui C, Zhao Z, Ye K, Shi H, et al. Endovascular repair of aortic arch intramural hematoma and penetrating ulcers with 810 nm in situ laser-assisted fenestration: preliminary results of a single-center. *Lasers Surg Med* 2018;50:837-43.
154. Cires G, Noll RE Jr, Albuquerque FC Jr, Tonnessen BH, Sternbergh WC 3rd. Endovascular debranching of the aortic arch during thoracic endograft repair. *J Vasc Surg* 2011;53:1485-91.
155. Criado FJ. A percutaneous technique for preservation of arch branch patency during thoracic endovascular aortic repair (TEVAR): retrograde catheterization and stenting. *J Endovasc Ther* 2007;14:54-8.
156. Patel HJ, Dake MD, Bavaria JE, Singh MJ, Filinger M, Fischbein MP, et al. Branched endovascular therapy of the distal aortic arch: preliminary results of the feasibility multicenter trial of the Gore thoracic branch endoprosthesis. *Ann Thorac Surg* 2016;102:1190-8.
157. Roselli EE, Arko FR 3rd, Thompson MM. Results of the Valiant Mona LSA early feasibility study for descending thoracic aneurysms. *J Vasc Surg* 2015;62:1465-71.e3.
158. Drews JD, Patel HJ, Williams DM, Dasika NL, Deeb GM. The impact of acute renal failure on early and late outcomes after thoracic aortic endovascular repair. *Ann Thorac Surg* 2014;97:2027-33.
159. Piffaretti G, Mariscalco G, Bonardelli S, Sarcina A, Gelpi G, Bellosta R, et al. Predictors and outcomes of acute kidney injury after thoracic aortic endograft repair. *J Vasc Surg* 2012;56:1527-34.
160. Silver SA, Shah PM, Chertow GM, Harel S, Wald R, Harel Z. Risk prediction models for contrast induced nephropathy: systematic review. *BMJ* 2015;351:h4395.
161. Wichmann JL, Katzberg RW, Litwin SE, Zwerner PL, De Cecco CN, Vogl TJ, et al. Contrast-induced nephropathy. *Circulation* 2015;132:1931-6.
162. Eng J, Wilson RF, Subramaniam RM, Zhang A, Suarez-Cuervo C, Turban S, et al. Comparative effect of contrast media type on the incidence of contrast-induced nephropathy: a systematic review and meta-analysis. *Ann Intern Med* 2016;164:417-24.

163. Wang N, Qian P, Kumar S, Yan TD, Phan K. The effect of N-acetylcysteine on the incidence of contrast-induced kidney injury: a systematic review and trial sequential analysis. *Int J Cardiol* 2016;209:319-27.
164. Eng J, Subramaniam RM, Wilson R, Turban S, Choi MJ, Zhang A, et al. Contrast-induced nephropathy: comparative effects of different contrast media. Comparative Effectiveness Review No. 155. Rockville, Md: Agency for Healthcare Research and Quality (US); 2016.
165. Leon LR Jr, Mills JL Sr, Jordan W, Morasch MM, Kovacs M, Becker GJ, et al. The risks of celiac artery coverage during endoluminal repair of thoracic and thoracoabdominal aortic aneurysms. *Vasc Endovascular Surg* 2009;43:51-60.
166. Levin DC, Baltaxe HA. High incidence of celiac axis narrowing in asymptomatic individuals. *Am J Roentgenol Radium Ther Nucl Med* 1972;116:426-9.
167. Bron KM, Redman HC. Splanchnic artery stenosis and occlusion. Incidence; arteriographic and clinical manifestations. *Radiology* 1969;92:323-8.
168. Park CM, Chung JW, Kim HB, Shin SJ, Park JH. Celiac axis stenosis: incidence and etiologies in asymptomatic individuals. *Korean J Radiol* 2001;2:8-13.
169. Song SY, Chung JW, Kwon JW, Joh JH, Shin SJ, Kim HB, et al. Collateral pathways in patients with celiac axis stenosis: angiographic-spiral CT correlation. *Radiographics* 2002;22:881-93.
170. Gawenda M, Libicher M. Imaging to estimate the safety of intentional celiac trunk coverage in TEVAR: multislice CTA cannot replace angiography at present. *J Endovasc Ther* 2009;16:55-8; discussion: 58-9.
171. Hyhlik-Durr A, Geisbusch P, von Tengg-Kobligh H, Klemm K, Bockler D. Intentional overstenting of the celiac trunk during thoracic endovascular aortic repair: preoperative role of multislice CT angiography. *J Endovasc Ther* 2009;16:48-54.
172. Libicher M, Reichert V, Aleksic M, Brunkwall J, Lackner KJ, Gawenda M. Balloon occlusion of the celiac artery: a test for evaluation of collateral circulation prior endovascular coverage. *Eur J Vasc Endovasc Surg* 2008;36:303-5.
173. Mehta M, Darling RC 3rd, Taggart JB, Roddy SP, Sternbach Y, Ozsvath KJ, et al. Outcomes of planned celiac artery coverage during TEVAR. *J Vasc Surg* 2010;52:1153-8.
174. Rose MK, Pearce BJ, Matthews TC, Patterson MA, Passman MA, Jordan WD. Outcomes after celiac artery coverage during thoracic endovascular aortic aneurysm repair. *J Vasc Surg* 2015;62:36-42.
175. Vaddineni SK, Taylor SM, Patterson MA, Jordan WD Jr. Outcome after celiac artery coverage during endovascular thoracic aortic aneurysm repair: preliminary results. *J Vasc Surg* 2007;45:467-71.
176. Ayad M, Senders ZJ, Ryan S, Abai B, DiMuzio P, Salvatore DM. Chronic mesenteric ischemia after partial coverage of the celiac artery during TEVAR, case report, and review of the literature. *Ann Vasc Surg* 2014;28:1935.e1-6.
177. Illig KA, Ohki T, Hughes GC, Kato M, Shimizu H, Patel HJ, et al. One-year outcomes from the international multicenter study of the Zenith Alpha Thoracic Endovascular Graft for thoracic endovascular repair. *J Vasc Surg* 2015;62:1485-94.
178. Moore WS, Rutherford RB. Transfemoral endovascular repair of abdominal aortic aneurysm: results of the North American EVT phase 1 trial. *EVT Investigators. J Vasc Surg* 1996;23:543-53.
179. Caiati JM, Kaplan D, Gitlitz D, Hollier LH, Marin ML. The value of the oblique groin incision for femoral artery access during endovascular procedures. *Ann Vasc Surg* 2000;14:248-53.
180. Chuter TA, Reilly LM, Stoney RJ, Messina LM. Femoral artery exposure for endovascular aneurysm repair through oblique incisions. *J Endovasc Surg* 1998;5:259-60.
181. Nelson PR, Kracjer Z, Kansal N, Rao V, Bianchi C, Hashemi H, et al. A multicenter, randomized, controlled trial of totally percutaneous access versus open femoral exposure for endovascular aortic aneurysm repair (the PEVAR trial). *J Vasc Surg* 2014;59:1181-93.
182. de Souza LR, Oderich GS, Banga PV, Hofer JM, Wigham JR, Cha S, et al. Outcomes of total percutaneous endovascular aortic repair for thoracic, fenestrated, and branched endografts. *J Vasc Surg* 2015;62:1442-9.
183. Lee WA, Brown MP, Nelson PR, Huber TS. Total percutaneous access for endovascular aortic aneurysm repair ("Preclose" technique). *J Vasc Surg* 2007;45:1095-101.
184. Bensley RP, Hurks R, Huang Z, Pomposelli F, Hamdan A, Wyers M, et al. Ultrasound-guided percutaneous endovascular aneurysm repair success is predicted by access vessel diameter. *J Vasc Surg* 2012;55:1554-61.
185. Skagius E, Bosnjak M, Bjorck M, Steuer J, Nyman R, Wanhainen A. Percutaneous closure of large femoral artery access with Prostar XL in thoracic endovascular aortic repair. *Eur J Vasc Endovasc Surg* 2013;46:558-63.
186. Sarmiento JM, Wisniewski PJ, Do NT, Slezak JM, Tayyarah M, Aka PK, et al. The Kaiser Permanente experience with ultrasound-guided percutaneous endovascular abdominal aortic aneurysm repair. *Ann Vasc Surg* 2012;26:906-12.
187. Jaffan AA, Prince EA, Hampson CO, Murphy TP. The preclose technique in percutaneous endovascular aortic repair: a systematic literature review and meta-analysis. *Cardiovasc Intervent Radiol* 2013;36:567-77.
188. Zakko J, Scali S, Beck AW, Klodell CT Jr, Beaver TM, Martin TD, et al. Percutaneous thoracic endovascular aortic repair is not contraindicated in obese patients. *J Vasc Surg* 2014;60:921-8.
189. Greenberg RK, O'Neill S, Walker E, Haddad F, Lyden SP, Svensson LG, et al. Endovascular repair of thoracic aortic lesions with the Zenith TX1 and TX2 thoracic grafts: intermediate-term results. *J Vasc Surg* 2005;41:589-96.
190. Tsilimparis N, Dayama A, Perez S, Ricotta JJ 2nd. Iliac conduits for endovascular repair of aortic pathologies. *Eur J Vasc Endovasc Surg* 2013;45:443.
191. Criado FJ. Iliac arterial conduits for endovascular access: technical considerations. *J Endovasc Surg* 2007;14:347-51.
192. Parmer SS, Carpenter JP. Techniques for large sheath insertion during endovascular thoracic aortic aneurysm repair. *J Vasc Surg* 2006;43(Suppl A):62A-8A.
193. Peterson BC, Matsumura JS. Internal endoconduit: an innovative technique to address unfavorable iliac artery anatomy encountered during thoracic endovascular aortic repair. *J Vasc Surg* 2008;47:441-5.
194. van Bogerijen GH, Williams DM, Eliason JL, Dasika NL, Deeb GM, Patel HJ. Alternative access techniques with thoracic endovascular aortic repair, open iliac conduit versus endoconduit technique. *J Vasc Surg* 2014;60:1168-76.
195. Oderich GS, Picada-Correa M, Pereira AA. Open surgical and endovascular conduits for difficult access during endovascular aortic aneurysm repair. *Ann Vasc Surg* 2012;26:1022-9.
196. Wu T, Carson JC, Skelly CL. Use of internal endoconduits as an adjunct to endovascular aneurysm repair in the setting of challenging aortoiliac anatomy. *Ann Vasc Surg* 2010;24:114.e7-11.
197. Yano OJ, Faries PL, Morrissey N, Teodorescu V, Hollier LH, Marin ML. Ancillary techniques to facilitate endovascular repair of aortic aneurysms. *J Vasc Surg* 2001;34:69-75.

198. Asano S, Hayashida N, Shibata Y, Koizumi S, Ito T, Ikeuchi H, et al. A case of thoracic endovascular aortic repair using carotid access with axillary-carotid bypass for descending aortic aneurysm in a patient with aortoiliac occlusive disease. *Ann Vasc Dis* 2019;12:105-8.
199. Johansson G, Markstrom U, Swedenborg J. Ruptured thoracic aortic aneurysms: a study of incidence and mortality rates. *J Vasc Surg* 1995;21:985-8.
200. Cambria RP, Crawford RS, Cho JS, Bavaria J, Farber M, Lee WA, et al. A multicenter clinical trial of endovascular stent graft repair of acute catastrophes of the descending thoracic aorta. *J Vasc Surg* 2009;50:1255-64.e1-4.
201. Schermerhorn ML, Giles KA, Hamdan AD, Dalhberg SE, Hagberg R, Pomposelli F. Population-based outcomes of open descending thoracic aortic aneurysm repair. *J Vasc Surg* 2008;48:821-7.
202. Conrad MF, Ergul EA, Patel VI, Paruchuri V, Kwolek CJ, Cambria RP. Management of diseases of the descending thoracic aorta in the endovascular era: a Medicare population study. *Ann Surg* 2010;252:603-10.
203. Jonker FH, Trimarchi S, Verhagen HJ, Moll FL, Sumpio BE, Muhs BE. Meta-analysis of open versus endovascular repair for ruptured descending thoracic aortic aneurysm. *J Vasc Surg* 2010;51:1026-32.
204. Jonker FH, Verhagen HJ, Lin PH, Heijmen RH, Trimarchi S, Lee WA, et al. Open surgery versus endovascular repair of ruptured thoracic aortic aneurysms. *J Vasc Surg* 2011;53:1210-6.
205. Botsios S, Fromke J, Walterbusch G, Schuermann K, Reinstadler J, Dohmen G. Endovascular treatment for nontraumatic rupture of the descending thoracic aorta: long-term results. *J Card Surg* 2014;29:353-8.
206. Ziza V, Canaud L, Molinari N, Branchereau P, Marty-Ane C, Alric P. Thoracic endovascular aortic repair: a single center's 15-year experience. *J Thorac Cardiovasc Surg* 2016;151:1595-603.e7.
207. Khashram M, He Q, Oh TH, Khanafer A, Wright IA, Vasudevan TM, et al. Late radiological and clinical outcomes of traumatic thoracic aortic injury managed with thoracic endovascular aortic repair. *World J Surg* 2016;40:1763-70.
208. Canaud L, Marty-Ane C, Ziza V, Branchereau P, Alric P. Minimum 10-year follow-up of endovascular repair for acute traumatic transection of the thoracic aorta. *J Thorac Cardiovasc Surg* 2015;149:825-9.
209. Meena RA, Benarroch-Campel J, Leshnower BG, Escobar GA, Duwayri Y, Jordan WD Jr, et al. Surveillance recommendations following TEVAR should be based on initial indication for repair. *Ann Vasc Surg* 2019;57:51-9.
210. Janosi RA, Gorla R, Tsagakis K, Kahlert P, Horacek M, Bruckschen F, et al. Thoracic endovascular repair of complicated penetrating aortic ulcer: an 11-year single-center experience. *J Endovasc Ther* 2016;23:150-9.
211. von Allmen RS, Anjum A, Powell JT. Outcomes after endovascular or open repair for degenerative descending thoracic aortic aneurysm using linked hospital data. *Br J Surg* 2014;101:1244-51.
212. Oliveira N, Bastos Goncalves F, Ten Raa S, Rouwet E, Hendriks JM, Cassio I, et al. Do we need long-term follow-up after EVAR and TEVAR or can we simplify surveillance protocols? *J Cardiovasc Surg (Torino)* 2014;55(Suppl 1):151-8.
213. Spiliotopoulos K, Kokotsakis J, Argiriou M, Dedeilias P, Farsaris D, Diamantis T, et al. Endovascular repair for blunt thoracic aortic injury: 11-year outcomes and postoperative surveillance experience. *J Thorac Cardiovasc Surg* 2014;148:2956-61.
214. Canaud L, Alric P, Gandet T, Albat B, Marty-Ane C, Berthet JP. Surgical conversion after thoracic endovascular aortic repair. *J Thorac Cardiovasc Surg* 2011;142:1027-31.
215. Melissano G, Tshomba Y, Mascia D, Baccellieri D, Kahlberg A, Bertoglio L, et al. Late open conversion after TEVAR. *J Cardiovasc Surg (Torino)* 2016;57:491-7.
216. Calligaro KD, Toursarkissian B, Clagett GP, Towne J, Hodgson K, Moneta G, et al; Clinical Practice Council, Society for Vascular Surgery. Guidelines for hospital privileges in vascular and endovascular surgery: recommendations of the Society for Vascular Surgery. *J Vasc Surg* 2008;47:1-5.
217. Hodgson KJ, Matsumura JS, Ascher E, Dake MD, Sacks D, Krol K, et al. Clinical competence statement on thoracic endovascular aortic repair (TEVAR)—multispecialty consensus recommendations. A report of the SVS/SIR/SCAI/SVMB Writing Committee to Develop a Clinical Competence Standard for TEVAR. *J Vasc Surg* 2006;43:858-62.
218. Goodney PP, Brooke BS, Wallaert J, Travis L, Lucas FL, Goodman DC, et al. Thoracic endovascular aneurysm repair, race, and volume in thoracic aneurysm repair. *J Vasc Surg* 2013;57:56-63.
219. Patel VI, Mukhopadhyay S, Ergul E, Aranson N, Conrad MF, Lamuraglia GM, et al. Impact of hospital volume and type on outcomes of open and endovascular repair of descending thoracic aneurysms in the United States Medicare population. *J Vasc Surg* 2013;58:346-54.
220. Schaffer JM, Lingala B, Miller DC, Woo YJ, Mitchell RS, Dake MD. Midterm survival after thoracic endovascular aortic repair in more than 10,000 Medicare patients. *J Thorac Cardiovasc Surg* 2015;149:808-20; discussion: 820-3.

Submitted May 27, 2020; accepted May 29, 2020.